CHAPTER 4: MUSCULO-SKELETAL SYSTEM

At the end of this chapter, student will be able to:

a) Describe the functions of the skeleton.
b) Explain how bones are classified, and give an example of each type.
c) Describe how the embryonic skeleton model is replaced by bone.
d) Name the nutrients necessary for bone growth, and explain their functions.
e) Name the hormones involved in bone growth and maintenance, and explain their functions.
f) Explain what is meant by "exercise" for bones, and explain its importance.
g) Name all the bones of the human skeleton (be able to point to each on diagrams, skeleton models, or yourself).
h) Describe the functions of the skull, vertebral column, rib cage, scapula, and pelvic bone.
i) Explain how joints are classified. For each type, give an example, and describe the movement possible.
j) Describe the parts of a synovial joint, and explain their functions.
k) Name the organ systems directly involved in movement, and state how they are involved.
l) Describe muscle structure in terms of muscle cells, tendons, and bones.
m) Explain the role of the brain with respect to skeletal muscle.
n) Define muscle tone and explain its importance.
o) Define muscle sense and explain its importance.
p) Explain the importance of hemoglobin and myoglobin, oxygen debt, and lactic acid.
q) Describe the neuromuscular junction and state the function of each part.
r) Describe some of the body's responses to exercise and explain how each maintains homeostasis.
s) Learn the major muscles of the body and their functions.

4.0. INTRODUCTION

Locomotive system or musculo-skeletal system regroups two systems: Skeletal system and muscular system. The two systems contribute to the movement. Muscles are attached to the bones by tendons. Bones work together with muscles as simple mechanical lever systems to produce body movement.

4.1. SKELETAL SYSTEM

4.1.1. Function of the Skeletal System

Humans are vertebrates, animals having a vertebral column or backbone. They rely on a sturdy internal frame that is centered on a prominent spine. The human skeletal system consists of bones, cartilage, ligaments and tendons and accounts for about 20 percent of the body weight. The living bones in our bodies use oxygen and give off waste products in metabolism. They contain active tissues that consume nutrients, require a blood supply and change shape or remodel in response to variations in mechanical stress.

- *Bones provide a rigid frame work, known as the skeleton* that support and protect the soft organs of the body. The skeleton supports the body against the pull of gravity. The large bones of the lower limbs support the trunk when standing.
- *The skeleton also protects the soft body parts*. The fused bones of the cranium surround the brain to make it less vulnerable to injury. Vertebrae surround and protect the spinal cord and bones of the rib cage help protect the heart and lungs of the thorax.
- Bones work together with muscles as simple mechanical lever systems to *produce body movement.*
- *Bones contain more calcium than any other organ*. The intercellular matrix of bone contains large amounts of calcium salts, the most important being calcium phosphate. When blood calcium levels decrease below normal, calcium is released from the bones so that there will be an adequate supply for metabolic needs. When blood calcium levels are increased, the excess calcium is stored in the bone matrix. The dynamic process of *releasing and storing calcium* goes on almost continuously.

- *Hematopoiesis*, the formation of blood cells, mostly takes place in the red marrow of the bones. In infants, red marrow is found in the bone cavities. With age, it is largely replaced by yellow marrow for fat storage. In adults, red marrow is limited to the spongy bone in the skull, ribs, sternum, clavicles, vertebrae and pelvis. Red marrow functions in the formation of red blood cells, white blood cells and blood platelets.

4.1.2. Structure of Bone Tissue

There are two types of bone tissue: *compact* and *spongy*. The names imply that the two types differ in density, or how tightly the tissue is packed together. There are three types of cells that contribute to bone homeostasis. *Osteoblasts* are bone-forming cell, *osteoclasts* resorb or break down bone, and *osteocytes* are mature bone cells. An equilibrium between osteoblasts and osteoclasts maintains bone tissue.

- **Compact Bone**

Compact bone consists of closely packed *osteons* or *haversian systems*. The osteon consists of a central canal called the osteonic (haversian) canal, which is surrounded by concentric rings (lamellae) of matrix. Between the rings of matrix, the bone cells (osteocytes) are located in spaces called lacunae. Small channels (canaliculi) radiate from the lacunae to the osteonic (haversian) canal to provide passageways through the hard matrix. In compact bone, the haversian systems are packed tightly together to form what appears to be a solid mass. The osteonic canals contain blood vessels that are parallel to the long axis of the bone. These blood vessels interconnect, by way of perforating canals, with vessels on the surface of the bone.

- **Spongy (Cancellous) Bone**

Spongy (cancellous) bone is lighter and less dense than compact bone. Spongy bone consists of plates (trabeculae) and bars of bone adjacent to small, irregular cavities that contain red bone marrow. The canaliculi connect to the adjacent cavities, instead of a central haversian canal, to receive their blood supply. It may appear that the trabeculae are arranged in a haphazard manner, but they are organized to provide maximum strength similar to braces that are used to support a building. The trabeculae of spongy bone follow the lines of stress and can realign if the direction of stress changes.

4.1.3. Classification of bones

Individual bones are classified according to their shape as **long, short, flat, or irregular**.

a) **Long bones**

They are longer than they are wide. Most bones of upper and lower limbs are long bones. The shaft of a long bone is the **diaphysis**, and the ends are called **epiphyses.**

The diaphysis is made of compact bone and is hollow, forming a canal within the shaft. This **marrow canal** (or medullary cavity) contains **bone marrow: red marrow** which is the site of blood cell formation, and **yellow marrow** which is mostly adipose tissue. The epiphyses are made of spongy bones (with also bone marrow in their spaces) covered with a thin layer of compact bone. Although red bone marrow is present in the epiphyses of children's bones, it is largely replaced by yellow bone marrow in adult bones. In the fetus, the spaces within bones are filled with red marrow. The conversion of red marrow to yellow marrow begins just before birth and continues well into adulthood. Yellow marrow completely replaces the red marrow in the long bones of the limbs, except some of the proximal part of the arm and thin bones. In some locations, there is a mixture of red and yellow marrow. For example, part of the hip bone(ilium) may contain 50% of red and 50% of yellow marrow.

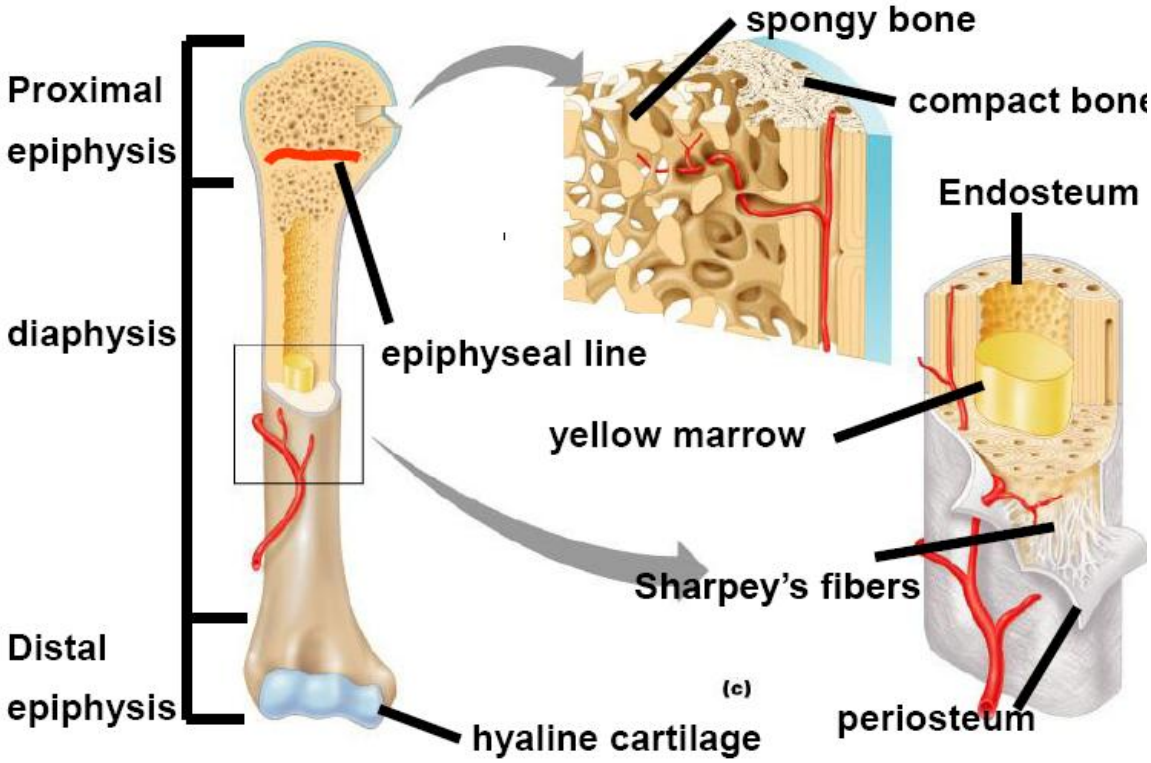

b) **Short bones** are about as broad as they are long, they are nearly cube-shaped or round and are exemplified by the bones of wrist (carpals) and ankles (tarsals).

c) **Flat bones** are relatively thin platelike and usually curved. Examples: certain skull bones, ribs, sternum, scapulae.

d) **Irregular bones** have varied shapes that permit connections with other bones. Examples: vertebrae, facial bones.

Short, flat, and irregular bones are all made of spongy bone covered with a thin layer of compact bone. Red bone marrow is found within the spongy bone.

The joint surfaces of bones are covered with **articular cartilage**, which provides a smooth surface. Covering the rest of the bone is the **periosteum**, a fibrous connective tissue membrane whose collagen fibers merge with those of the tendons and ligaments that are attached to the bone. The periosteum anchors these structures and contains both the blood vessels that enter the bone itself and osteoblasts that will become active if the bone is damaged.

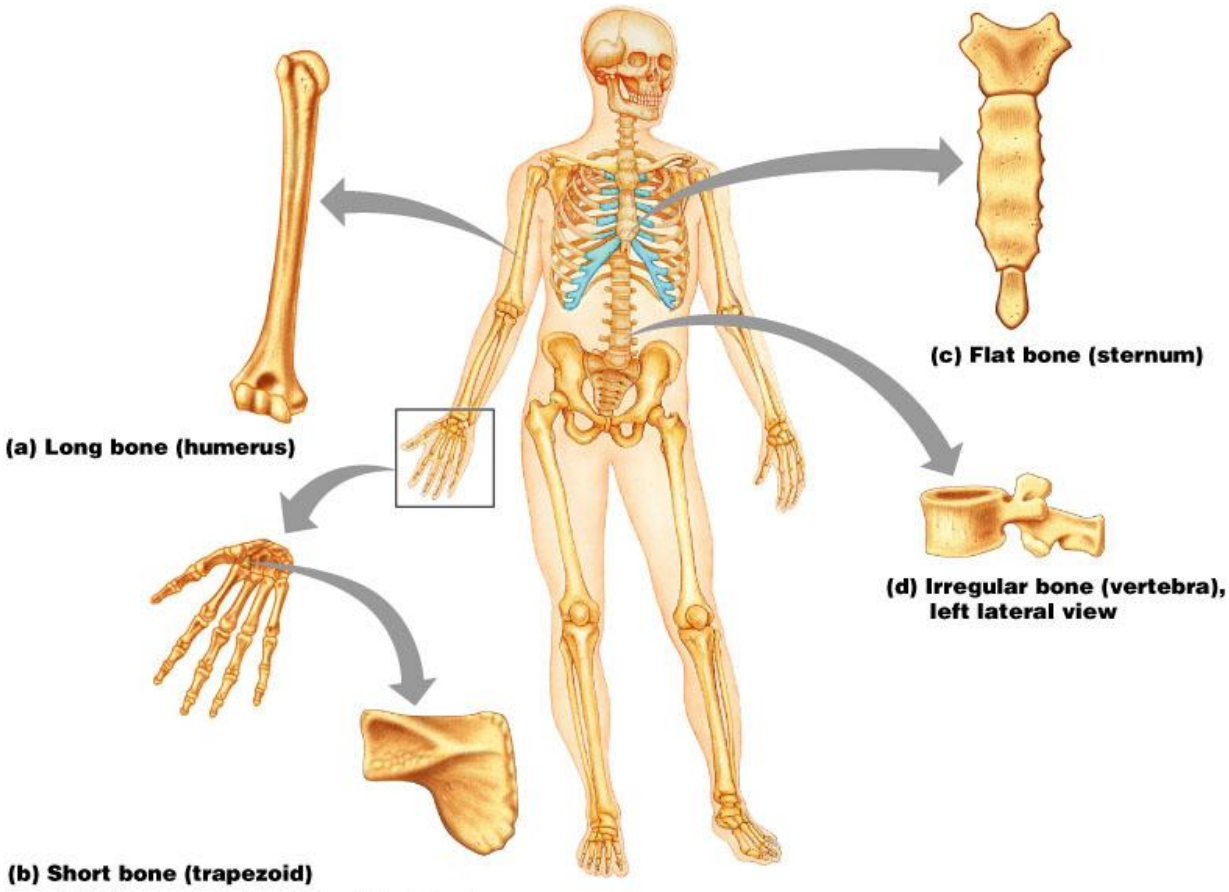

4.1.4. Bone Development

The terms ***osteogenesis*** and ***ossification*** are often used synonymously to indicate the process of bone formation. Parts of the skeleton form during the first few weeks after conception. By the end of the eighth week after conception, the skeletal pattern is formed in cartilage and connective tissue membranes and ossification begins. Bone development continues throughout adulthood. Even after adult stature is attained, bone development continues for repair of fractures and for remodeling to meet changing lifestyles. Osteoblasts, osteocytes and osteoclasts are the three cell types involved in the development, growth and remodeling of bones. Osteoblasts are bone-forming cells, osteocytes are mature bone cells and osteoclasts break down and reabsorb bone. There are two types of ossification: *intramembranous* and *endochondral*.

- ***Intramembranous***

Intramembranous ossification involves the replacement of sheet-like connective tissue membranes with bony tissue. Bones formed in this manner are called intramembranous bones. They include certain flat bones of the skull and some of the irregular bones. The future bones are first formed as connective tissue membranes. Osteoblasts migrate to the membranes and deposit bony matrix around them. When the osteoblasts are surrounded by matrix they are **called osteocytes.**

- ***Endochondral Ossification***

Endochondral ossification involves the replacement of hyaline cartilage with bony tissue. Most of the bones of the skeleton are formed in this manner. These bones are called endochondral bones. In this process, the future bones are first formed as hyaline cartilage models. During the third month after conception, the *perichondrium* that surrounds the hyaline cartilage "models" becomes infiltrated with blood vessels and osteoblasts and changes into a *periosteum*. The osteoblasts form a collar of compact bone around the diaphysis. At the same time, the cartilage in the center of the diaphysis begins to disintegrate. Osteoblasts penetrate the disintegrating cartilage and replace it with spongy bone. This forms a primary ossification center. Ossification continues from this center toward the ends of the bones. After spongy bone is formed in the diaphysis, osteoclasts break down the newly formed bone to open up the medullary cavity.

The cartilage in the epiphyses continues to grow so the developing bone increases in length. Later, usually after birth, secondary ossification centers form in the epiphyses. Ossification in the epiphyses is similar to that in the diaphysis except that the spongy bone is retained instead of being broken down to forms a medullary cavity. When secondary ossification is complete, the hyaline cartilage is totally replaced by bone except in two areas. A region of hyaline cartilage remains over the surface of the epiphysis as the articular cartilage and another area of cartilage remains between the epiphysis and diaphysis. This is the epiphyseal plate or growth region.

4.1.5. Bone Growth

Bones grow in length at the epiphyseal plate by a process that is similar to endochondral ossification. The cartilage in the region of the epiphyseal plate next to the epiphysis continues to grow by mitosis. The chondrocytes, in the region next to the diaphysis, age and degenerate. Osteoblasts move in and ossify the matrix to form bone. This process continues throughout childhood and the adolescent years until the cartilage growth slows and finally stops. When cartilage growth ceases, usually in the early twenties, the epiphyseal plate completely ossifies so that only a thin epiphyseal line remains and the bones can no longer grow in length. Bone growth is under the influence of growth hormone from the anterior pituitary gland and sex hormones from the ovaries and testes. Even though bones stop growing in length in early adulthood, they can continue to increase in thickness or diameter throughout life in response to stress from increased muscle activity or to weight. The increase in diameter is called appositional growth. Osteoblasts in the periosteum form compact bone around the external bone surface. At the same time, osteoclasts in the endosteum break down bone on the internal bone surface, around the medullary cavity. These two processes together increase the diameter of the bone and, at the same time, keep the bone from becoming excessively heavy and bulky.

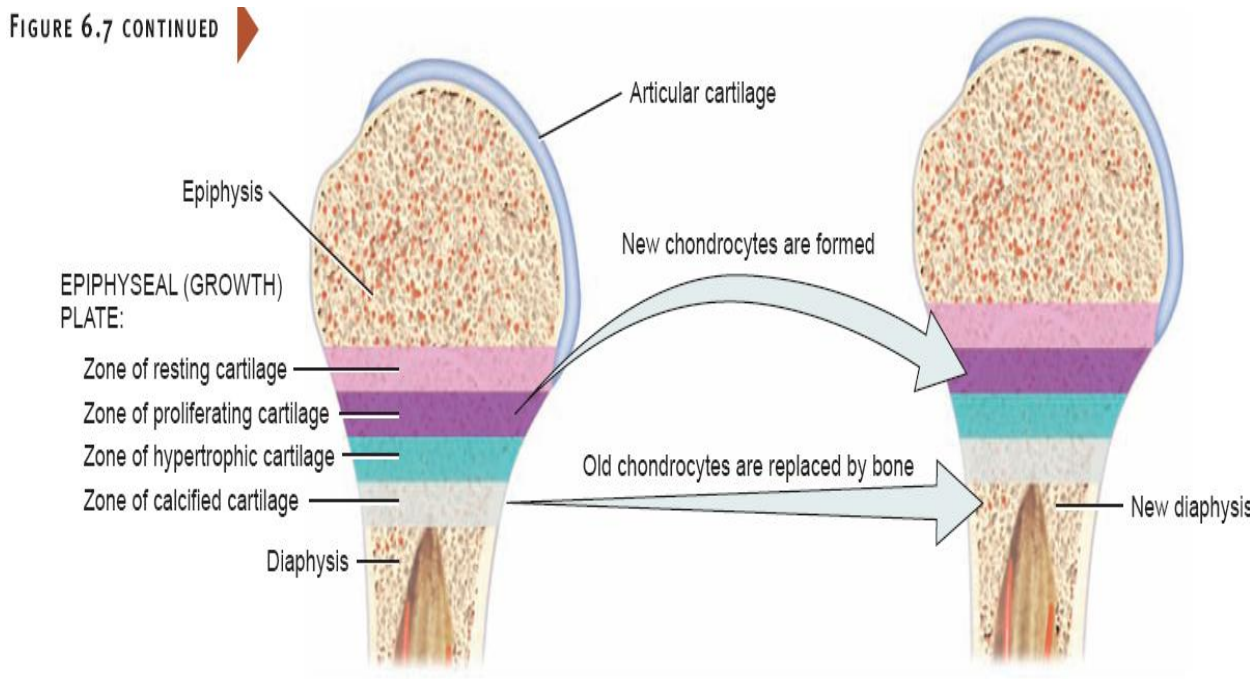

Figure: Lengthwise growth of bone at epiphyseal plate

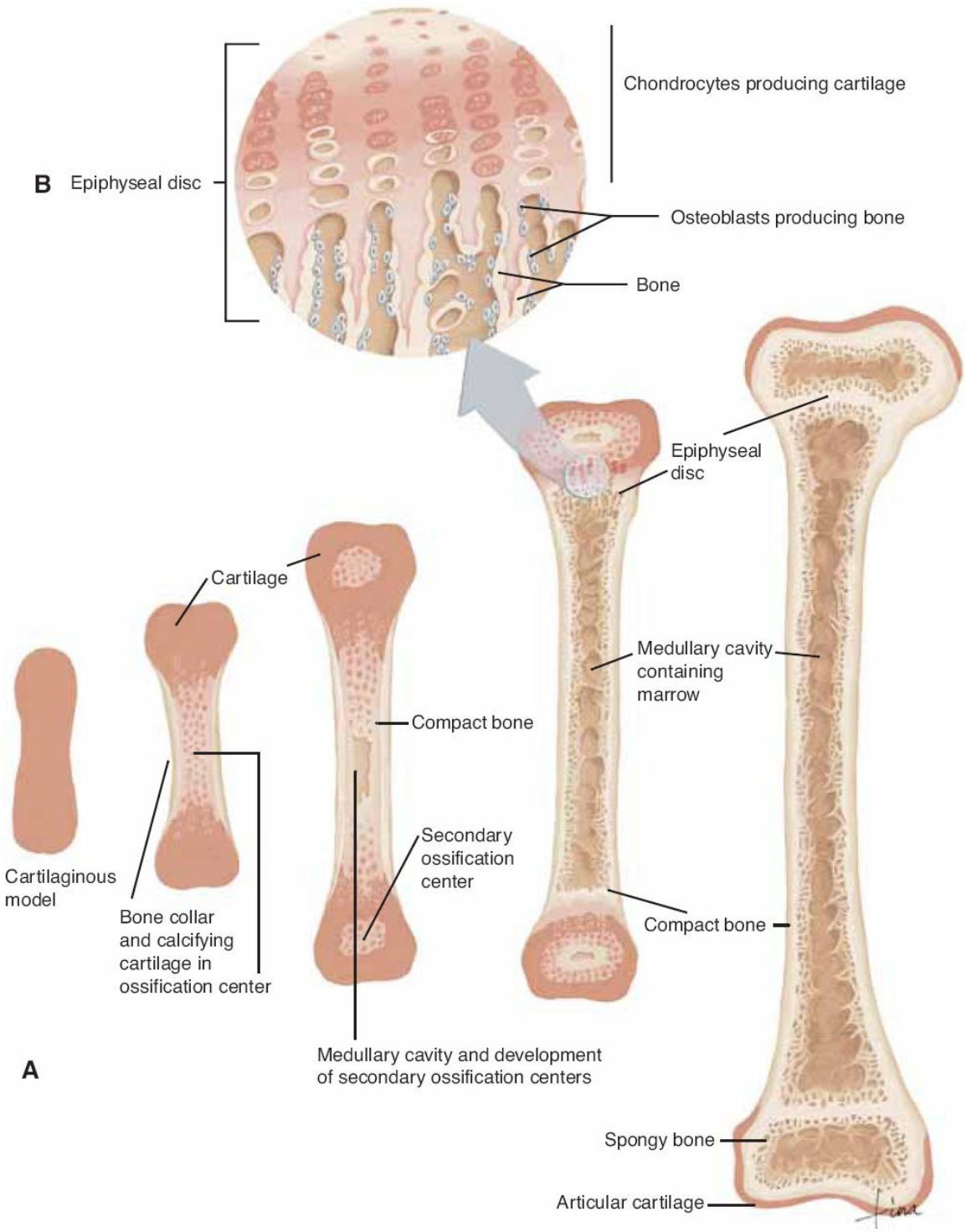

Figure: The ossification process in a long bone. (**A**) Progression of ossification from the cartilage model of the embryo to the bone of a young adult. (**B**) Microscopic view of an epiphyseal disc showing cartilage production and bone replacement.

4.1.6. Factors that affect bone growth and maintenance

1. Heredity: each person has a genetic potential for height, that is, a maximum height, with genes inherited from both parents. Many genes are involved, and their interactions are not well understood.Some of these genes are probably those for the enzymes involved in cartilage and bone production, for this is how bones grow.

2. Nutrition: nutrients are the raw materials of which bones are made. Calcium, phosphorus, and protein become part of the bone matrix itself.Vitamin D is needed for the efficient absorption of calcium and phosphorus by the small intestine.Vitamins A and C do not become part of bone but are necessary for the process of bone matrix formation (ossification). Without these and other nutrients, bones cannot grow properly. Children who are malnourished grow very slowly and may not reach their genetic potential for height.

3. Hormones: endocrine glands produce hormones that stimulate specific effects in certain cells. Several hormones make important contributions to bone growth and maintenance. These include growth hormone, thyroxine, parathyroid hormone, and insulin, which help regulate cell division, protein synthesis, calcium metabolism, and energy production. The sex hormones estrogen or testosterone help bring about the cessation of bone growth.

HORMONES INVOLVED IN BONE GROWTH AND MAINTENANCE

Hormones	**Functions**
Growth hormone (anterior pituitary gland)	•Increases the rate of mitosis of chondrocytes and osteoblasts •Increases the rate of protein synthesis (collagen, cartilage matrix,and enzymes for cartilage and bone formation)
Thyroxine (thyroid gland)	•Increases the rate of protein synthesis •Increases energy production from all food types
Insulin (pancreas)	Increases energy production from glucose
Parathyroid hormone (parathyroid glands)	•Increases the reabsorption of calcium from bones to the blood (raises blood calciumlevel) • Increases the absorption of calcium by the small intestine and kidneys(to the blood)

Calcitonin (thyroid gland)	•Decreases the reabsorption of calcium from bones (lowers blood calcium level)
Estrogen (ovaries)	•Promotes closure of the epiphyses of long bones (growth stops)
Testosterone (testes)	•Helps retain calcium in bones to maintain a strong bone matrix

4. Exercise or "stress": for bones, exercise means bearing weight, which is just what bones, are specialized to do. Without this stress (which is normal), bones will lose calcium faster than it is replaced. Exercise need not be strenuous; it can be as simple as the walking involved in everyday activities. Bones that do not get this exercise, such as those of patients confined to bed, will become thinner and more fragile.

4.1.7. Divisions of the Skeleton

The adult human skeleton usually consists of 206 named bones. These bones can be grouped in two divisions: axial skeleton and Appendicular skeleton. The 80 bones of the axial skeleton form the vertical axis of the body. They include the bones of the head, vertebral column, ribs and breastbone or sternum. The Appendicular skeleton consists of 126 bones and includes the free appendages and their attachments to the axial skeleton. The free appendages are the upper and lower extremities, or limbs, and their attachments which are called girdles. The named bones of the body are listed below by category.

A. Axial Skeleton (80 bones)

⇨ skull, sternum, ribs, and vertebrae (including sacrum)

1° SKULL

The **skull** consists of 8 cranial bones and 14 facial bones. Also in the head are three small bones in each middle ear cavity and the hyoid bone that supports the base of the tongue. The **cranial bones** form the braincase (lined with the meninges) that encloses and protects the brain, eyes,

and ears. The names of some of these bones will be familiar to you; they are the same as the terminology used to describe areas of the head. These are the frontal bone, parietal bones (two), temporal bones (two), and occipital bone. The sphenoid bone and ethmoid bone are part of the floor of the braincase and the orbits (sockets) for the eyes. The **frontal bone** forms the forehead and the anterior part of the top of the skull.

Parietal means "wall," and the two large **parietal bones** form the posterior top and much of the side walls of the skull. Each **temporal bone** on the side of the skull contains an external auditory meatus (ear canal), a middle ear cavity, and an inner ear labyrinth.

The **occipital bone** forms the lower, posterior part of the braincase. Its foramen magnum is a large opening for the spinal cord, and the two condyles (rounded projections) on either side articulate with the atlas, the first cervical vertebra. The **sphenoid bone** is said to be shaped like a bat, and the greater wing is visible on the side of the skull between the frontal and temporal bones. The body of the bat has a depression called the sella turcica, which encloses the pituitary gland. The **ethmoid bone** has a vertical projection called the crista galli ("rooster's comb") that anchors the cranial meninges.The rest of the ethmoid bone forms the roof and upper walls of the nasal cavities, and the upper part of the nasal septum.

All of the joints between cranial bones are immovable joints called **sutures**. It may seem strange to refer to a joint without movement, but the term *joint* (or *articulation*) is used for any junction of two bones. In a suture, the serrated, or sawtooth, edges of adjacent bones fit into each other. These interlocking projections prevent sliding or shifting of the bones if the skull is subjected to a blow or pressure. ***The coronal suture*** between the frontal and parietal bones, ***the squamosal suture*** between the parietal and temporal bones, and the ***lambdoidal suture*** between the occipital and parietal bones,***the sagittal suture,*** where the two parietal bones articulate along the midline of the top of the skull.

Of the 14 **facial bones**, only the **mandible** (lower jaw) is movable; it forms a **condyloid joint** with each temporal bone. The other joints between facial bones are all sutures. The **maxillae** are the two upper jaw bones, which also form the anterior portion of the hard palate (roof of the mouth). Sockets for the roots of the teeth are found in the maxillae and the mandible. The two **nasal bones** form the bridge of the nose where they articulate with the frontal bone (the rest of the nose is supported by cartilage). There is a **lacrimal bone** at the medial side of each orbit; the

lacrimal canal contains the lacrimal sac, a passageway for tears. Each of the two **zygomatic bones** forms the point of a cheek, and articulates with the maxilla, frontal bone, and temporal bone. The two **palatine bones** are the posterior portion of the hard palate.

The plow-shaped **vomer** forms the lower part of the nasal septum; it articulates with the ethmoid bone. On either side of the vomer is the **conchae**, six scrolllike bones that curl downward from the sides of the nasal cavities; they help increase the surface area of the nasal mucosa. **Paranasal sinuses** are air cavities located in the maxillae and frontal, sphenoid, and ethmoid bones. As the name *paranasal* suggests, they open into the nasal cavities and are lined with **ciliated epithelium** continuous with the mucosa of the nasal cavities.

We are aware of our sinuses only when they become "stuffed up," which means that the mucus they produce cannot drain into the nasal cavities. This may happen during upper respiratory infections such as colds, or with allergies such as hay fever. These sinuses, however, do have functions: They make the skull lighter in weight, because air is lighter than bone, and they provide resonance for the voice, meaning more air to vibrate and thus deepen the pitch of the voice.

The **mastoid sinuses** are air cavities in the mastoid process of each temporal bone; they open into the middle ear. Before the availability of antibiotics, middle ear infections often caused mastoiditis, infection of these sinuses. Within each middle ear cavity are three **auditory bones**: the malleus, incus, and stapes. As part of the hearing process, these bones transmit vibrations from the eardrum to the receptors in the inner ear.

Skull

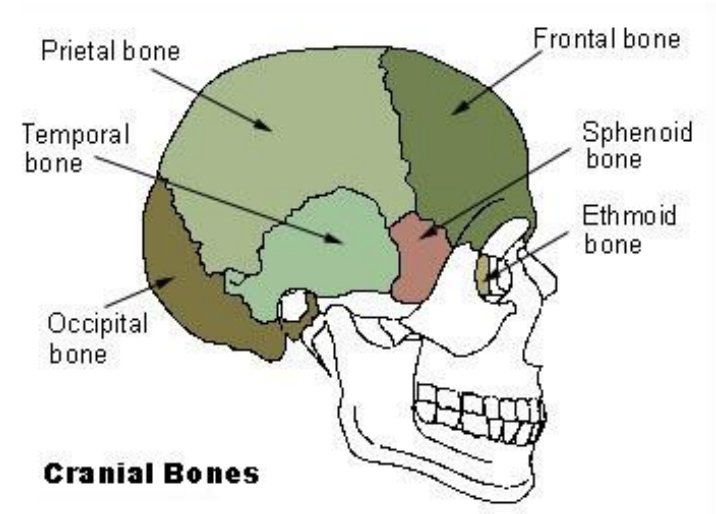

a) **Cranial Bones**

- Parietal (2)
- Temporal (2)
- Frontal (1)
- Occipital (1)
- Ethmoidal (1)

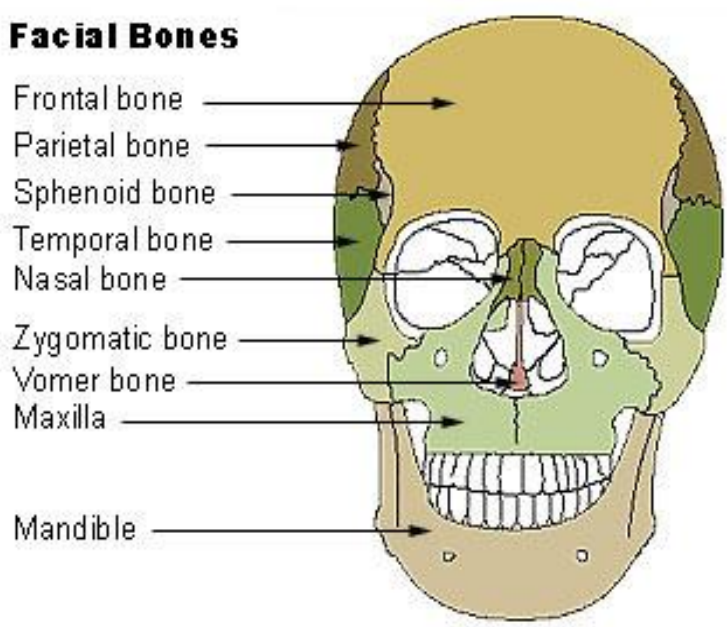

b) **Facial Bones**

- Maxilla (2)
- Zygomatic (2)
- Mandible (1)
- Nasal (2)
- Platine (2)
- Inferior nasal concha(2)
- Lacrimal (2)
- Vomer (1)

c) **Auditory Ossicles**

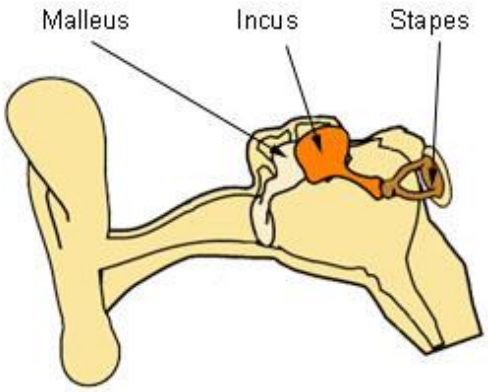

- Malleus (2)
- Incus (2)
- Stapes (2)

✓ **Hyoid (1)**

Cranial Bones

2° VERTEBRAL COLUMN

The **vertebral column** (spinal column or backbone) is made of individual bones called **vertebrae**. The names of vertebrae indicate their location along the length of the spinal column. There are 7 cervical vertebrae, 12 thoracic, 5 lumbar, 5 sacral fused into 1 sacrum, and 4 to 5 small coccygeal vertebrae fused into 1 coccyx. The seven **cervical vertebrae** are those within the neck. The first vertebra is called the **atlas**, which articulates with the occipital bone to support the skull and forms a **pivot joint** with the odontoid process of the **axis**, the second cervical vertebra. This pivot joint allows us to turn our heads from side to side. The remaining five cervical vertebrae do not have individual names. The **thoracic vertebrae** articulate (form joints) with the ribs on the posterior side of the trunk. The **lumbar vertebrae**, the largest and strongest bones of the spine, are found in the small of the back. The **sacrum** permits the articulation of the two hip bones: the **sacroiliac joints**. The **coccyx** is the remnant of tail vertebrae, and some muscles of the perineum (pelvic floor) are anchored to it.

All of the vertebrae articulate with one another in sequence, connected by ligaments, to form a flexible backbone that supports the trunk and head. They also form the **vertebral canal**, a continuous tunnel (lined with the meninges) within the bones that contain the spinal cord and protects it from mechanical injury. The spinous and transverse processes are projections for the

attachment of the muscles that bend the vertebral column. The facets of some vertebrae are small flat surfaces for articulation with other bones, such as the ribs with the facets of the thoracic vertebrae. The supporting part of a vertebra is its body; the bodies of adjacent vertebrae are separated by **discs** of fibrous cartilage. These discs cushion and absorb shock and permit some movement between vertebrae (**symphysis joints**).

Since there are so many joints, the backbone as a whole is quite flexible .The normal spine in anatomic position has fournatural curves, which are named after the vertebrae that form them, and notice that the cervical curve is forward, the thoracic curve backward,cartilages join the 7th rib cartilage. The last two pairs are called **floating ribs** because they do not articulate with the sternum at all. An obvious function of the rib cage is that it encloses and protects the heart and lungs. Keep in mind, though, that the rib cage also protects organs in the upper abdominal cavity, such as the liver and spleen.

The other important function of the rib cage depends upon its flexibility: The ribs are pulled upward and outward by the external intercostal muscles. This enlarges the chest cavity, which expands the lungs andcontributes to inhalation.

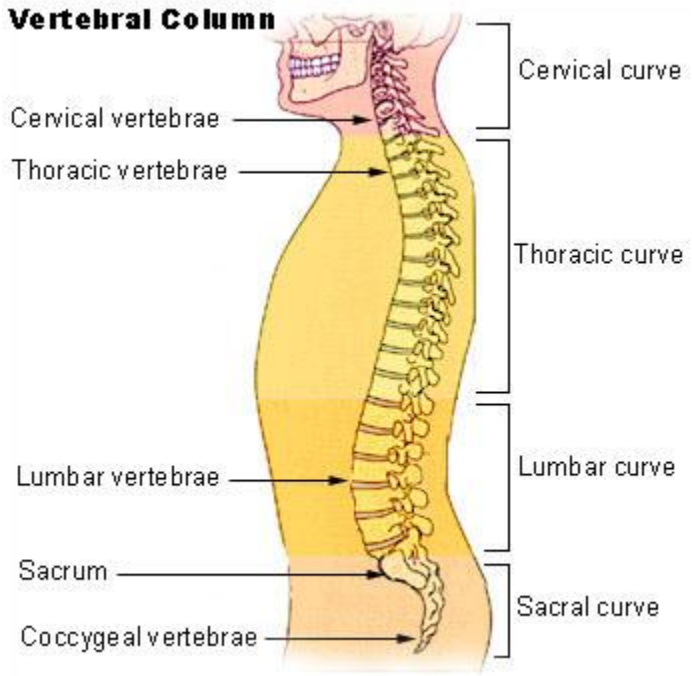

Vertebral Column

- Cervical vertebrae (7)
- Thoracic vertebrae (12)
- Lumbar vertebrae (5)
- Sacrum (1)
- Coccyx (1)

3° RIB CAGE

The **rib cage** consists of the 12 pairs of ribs and thesternum, or breastbone. The three parts of the sternumare the upper **manubrium**, **the central body**, and the lower **xiphoid process**. All of the **ribs** articulate posteriorly with the thoracic vertebrae. The first seven pairs of ribs are called **true ribs**; they articulate directly with the manubrium and body of the sternum by means of costal cartilages.The next three pairs are called **false ribs**; their cartilages join the 7th rib cartilage. The last two pairs are called **floating ribs** because they do not articulate with the sternum at all.An obvious function of the rib cage is that it encloses and protects the heart and lungs. Keep in mind, though, that the rib cage also protects organs in the upper abdominal cavity, such as the liver and spleen. The other important function of the rib cage depends upon its flexibility: The ribs are pulled upward and outward by the external intercostal muscles. This enlarges the chest cavity, which expands the lungs and contributes to inhalation.

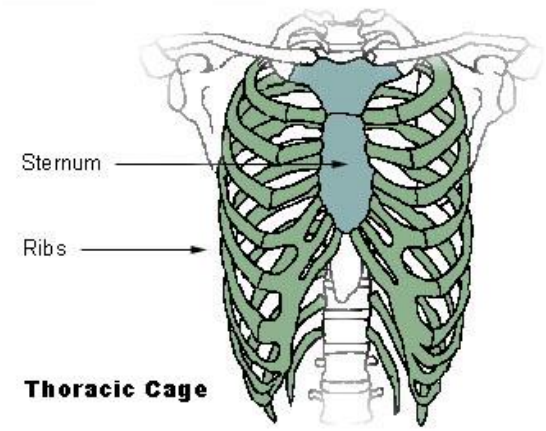

Thoracic Cage

- Sternum (1)
- Ribs (24

4° THE SHOULDER AND ARM

The shoulder girdles attach the arms to the axial skeleton.Each consists of a scapula (shoulder blade) and clavicle (collarbone). The **scapula** is a large, flat bone with several projections (the spine of the scapula, the coracoid process) that anchor some of the muscles that move the upper arm and the forearm. A shallow depression called the glenoid fossa forms a **ball-andsocket joint** with the humerus, the bone of the upperarm. Each **clavicle** articulates laterally with a scapula and medially with the manubrium of the sternum. In this position the clavicles act as braces for the scapulae and prevent the shoulders from coming too far forward. Although the shoulder joint is capable of a wide range of movement, the shoulder itself must be relatively

stable if these movements are to be effective. The **humerus** is the long bone of the upper arm. Proximally, the humerus forms a ball-and-socket joint with the scapula. Distally, the humerus forms a **hinge joint** with the ulna of the forearm. This hinge joint, the elbow, permits movement in one plane, that is, back and forth with no lateral movement.

The forearm bones are the **ulna** on the little finger side and the **radius** on the thumb side. The semilunar notch of the ulna is part of the hinge joint of the elbow; it articulates with the trochlea of the humerus. The radius and ulna articulate proximally to form a **pivot joint**, which permits turning the hand palm up to palm down. You can demonstrate this yourself by holding your arm palm up in front of you, and noting that the radius and ulna are parallel to each other. Then turn your hand palm down, and notice that your upper arm does not move. The radius crosses over the ulna, which permits the hand to perform a great variety of movements without moving the entire arm. The **carpals** are eight small bones in the wrist; **gliding joints** between them permit a sliding movement. The carpals also articulate with the distal ends of the ulna and radius, and with the proximal ends of the **metacarpals**, the five bones of the palm of the hand.

All of the joints formed by the carpals and metacarpals make the hand very flexible at the wrist (try this yourself: flexion to extension should be almost 180 degrees), but the thumb is more movable than the fingers because of its carpometacarpal joint. This is a **saddle joint**, which enables the thumb to cross over the palm, and permits gripping. The **phalanges** are the bones of the fingers. There are two phalanges in each thumb and three in each of the fingers. Between phalanges are **hinge joints**, which permit movement in one plane.

B. Appendicular Skeleton (126 bones)

The appendicular skeleton contains the bones of the pectoral girdle, upper limbs, pelvic girdle, and lower limbs.

1: Pectoral Girdle or shoulder girdle

The **pectoral girdle** (shoulder girdle) contains four bones: two clavicles and two scapulae. It supports the arms and serves as a place of attachment for muscles that move the arms.

- **Clavicles**

The **clavicles** (collarbones) are slender and S-shaped. Each clavicle articulates medially with the manubrium of the sternum. Each clavicle also articulates with a scapula. The clavicle serves as a support for the scapula and helps stabilize the shoulder.

(b) Superior view

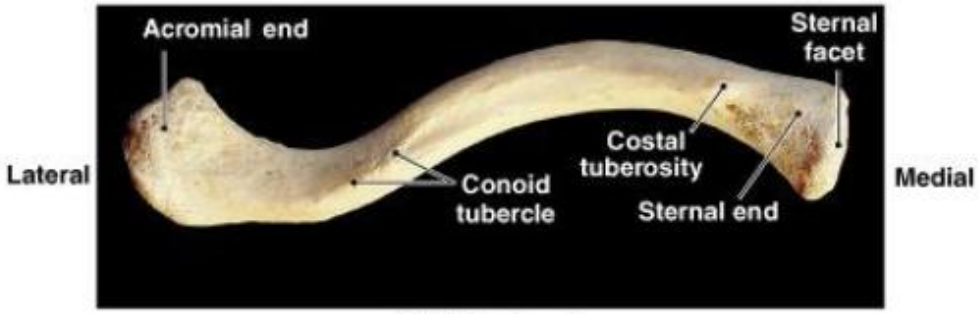

(c) Inferior view

- **Scapulae**

The **scapulae**, also called the shoulder blades, are large, flat bones that resemble to triangles.

One reason for the pectoral girdle's flexibility is that the scapulae are not joined to each other Each scapula has:

acromion process, which articulates with a clavicle and provides a place of attachment for arm and chest muscles;

The spine process, which extends from the acromion across the posterior surface of the scapula and divides that surface into a small **supraspinous fossa** superior to the spine and a large **infraspinous fossa** inferior to the spine.

coracoid process, which serves as a place of attachment for arm and chest muscles;

glenoid cavity, which articulates with the head of the arm bone (humerus). The pectoral girdle's flexibility is also a result of the glenoid cavity being smaller than the head of the humerus.

The Scapula

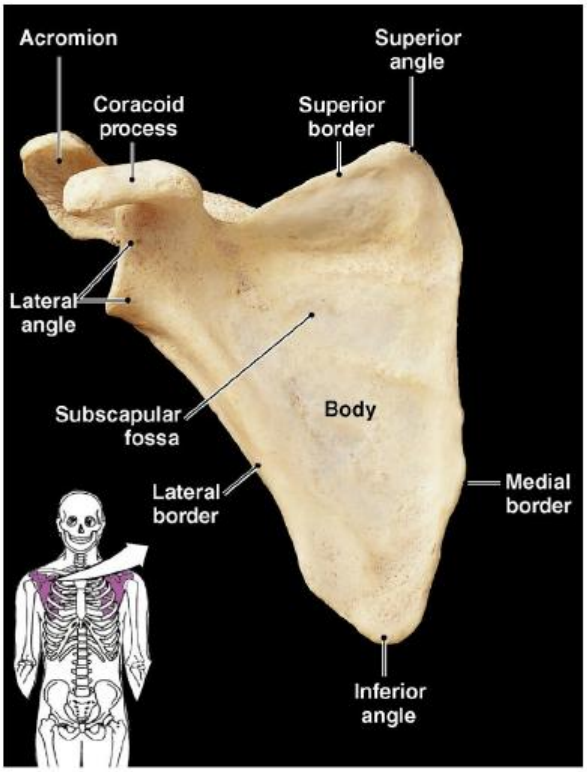

(a) Anterior view

2: Upper Limb

The upper limb includes the bones of the arm (humerus), the forearm (radius and ulna), and the hand (carpals, metacarpals, and phalanges).

- **Humerus**

The **humerus** is the only one bone of the arm. It is a long bone with the following features at the proximal end:

Head, which articulates with the glenoid cavity of the scapula;

Anatomical neck, immediately distal to the head;

Surgical neck, is so named because it is a common fracture site that often requires surgical repair.

Greater (on the lateral surface) and **lesser** (on the anterior) **tubercles,** provide attachments for muscles that move the arm and shoulder;

Intertubercular groove (bicipital), holds a tendon from the biceps brachii, a muscle of the arm;

Deltoid tuberosity, provides an attachment for the deltoid, a muscle that covers the shoulder joint.

At the distal end of humerus:

Capitulum, a lateral condyle that articulates with the head of the radius;

Trochlea, a spool-shaped condyle that articulates with the ulna;

Coronoid fossa, a depression for a process of the ulna when the elbow is flexed;

olecranon fossa, a depression for a process of the ulna when the elbow is extended.

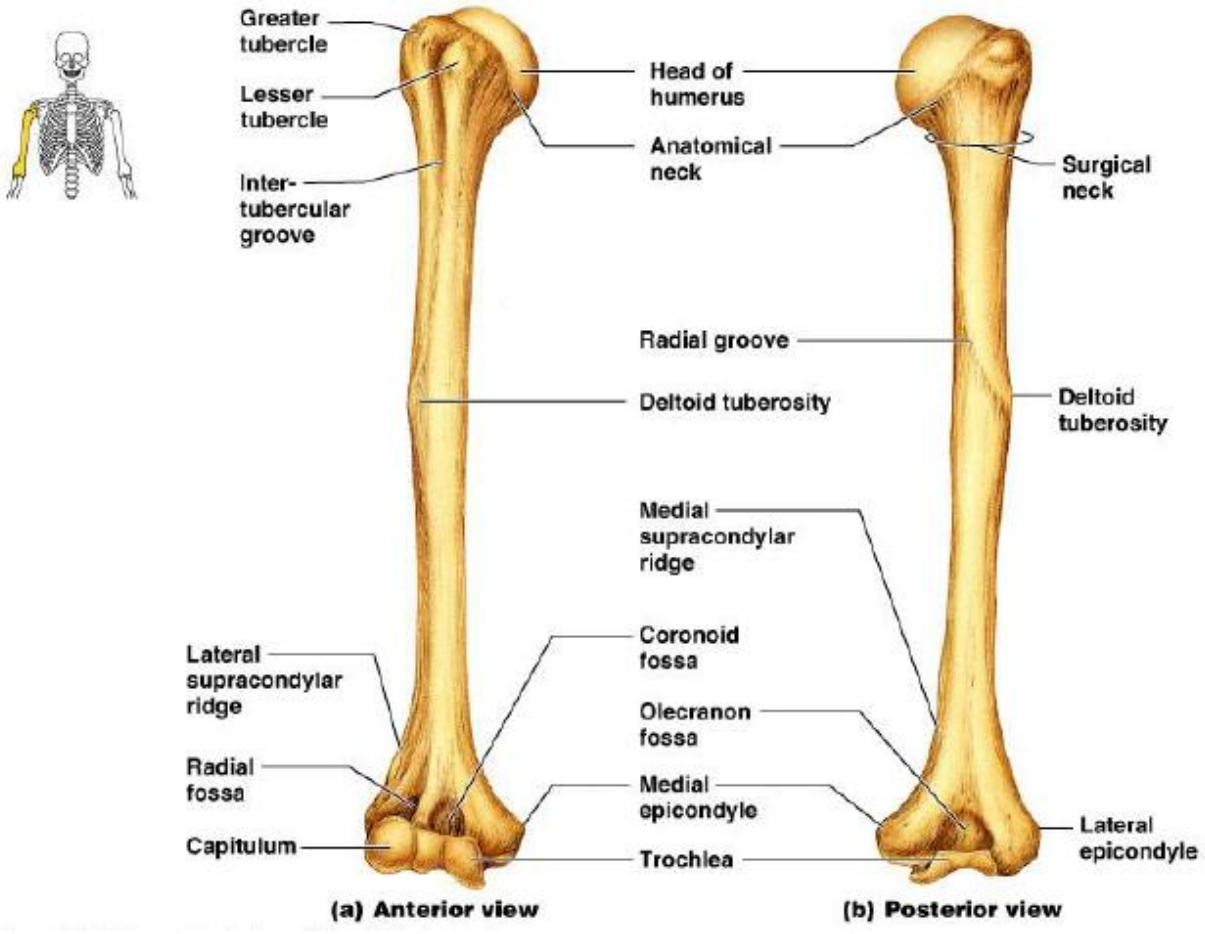

- **Radius**

The radius is on the lateral side of the forearm (the thumb side).

Proximally, the radius has the following features:

Head, which articulates with the capitulum of the humerus and fits into the radial notch of the ulna;

Radial tuberosity, which serves as a place of attachment for a tendon from the biceps brachii;

Distally, the radius has the following features:

Ulnar notch, which articulates with the head of the ulna;

Styloid process, which serves as a place of attachment for ligaments that run to the wrist.

- **Ulna**

The ulna is the longer bone of the forearm and is on the medial side of the forearm (the little finger side).

Proximally, the ulna has the following features:

Coronoid process, which articulates with the coronoid fossa of the humerus when the elbow is flexed;

Olecranon process, the point of the elbow, articulates with the olecranon fossa of the humerus when the elbow is extended;

Trochlear notch, which articulates with the trochlea of the humerus at the elbow joint;

Radial notch, which articulates with head of the radius.

Distally, the ulna has the following features:

Head, which articulates with the ulnar notch of the radius;

Styloid process, which serves as a place of attachment for ligaments that run to the wrist.

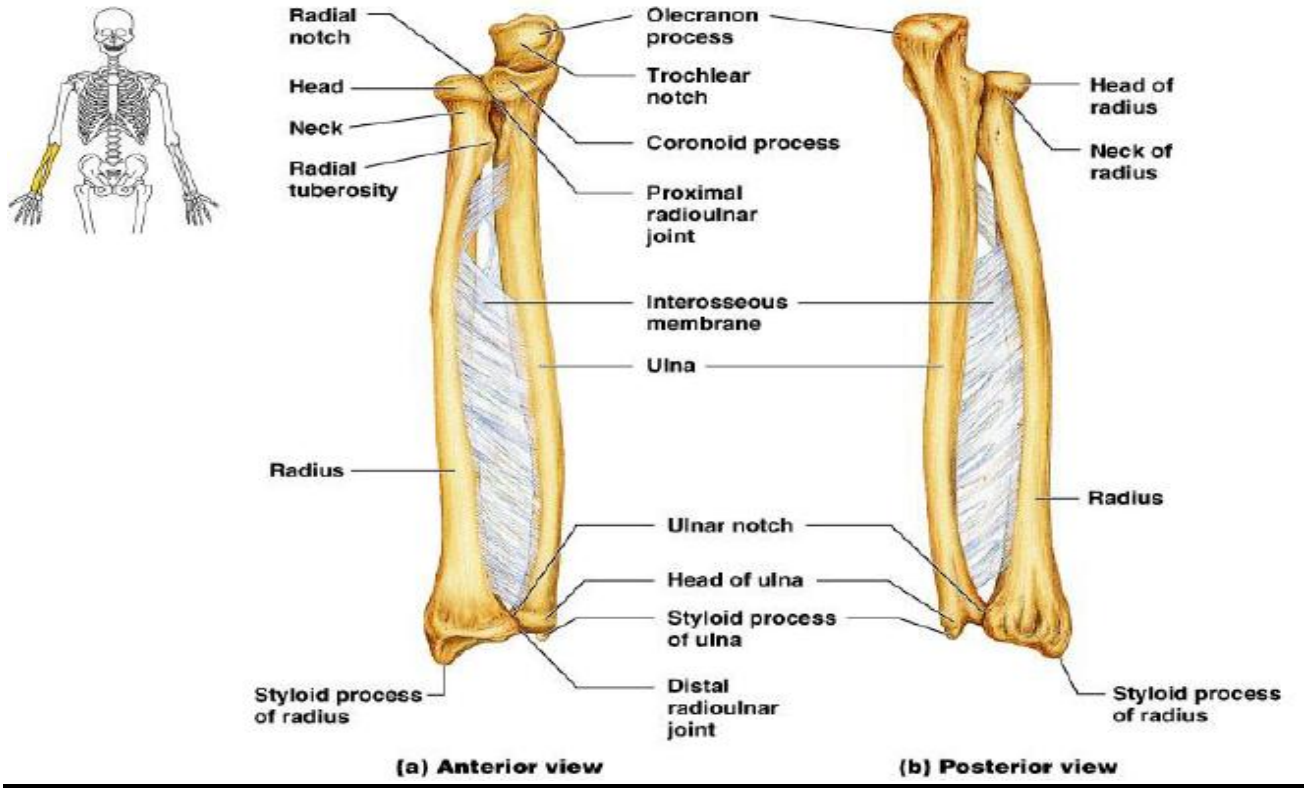

The wrist (Calpal bones)

The wrist, or carpus, contains eight small carpal bones, tightly bound by ligaments in two rows of four each.

The proximal row, lateral to medial includes: - Scaphoid

-Lunate
-Triquetrum
-Pisiform

The distal row, medial to lateral includes: -Hamate

-Capitate

-Trapezoid

-Trapezium

The hand

- **metacalpals**

They are attached to the calpal bonel bones and constitute bony framework of the hand.

They are numbered 1 to 5 numbered 1 to 5 from the base of thumb side toward the little finger, fan out to form the palm.

- **Phalanges**

The digits of each hand include one thumb and four fingers. Each digit consists of small long bones called phalanges.

The fingers, including the thumb, contain bones called. The thumb has only two phalanges (proximal and distal), but the other fingers have three each (proximal, middle, and distal).

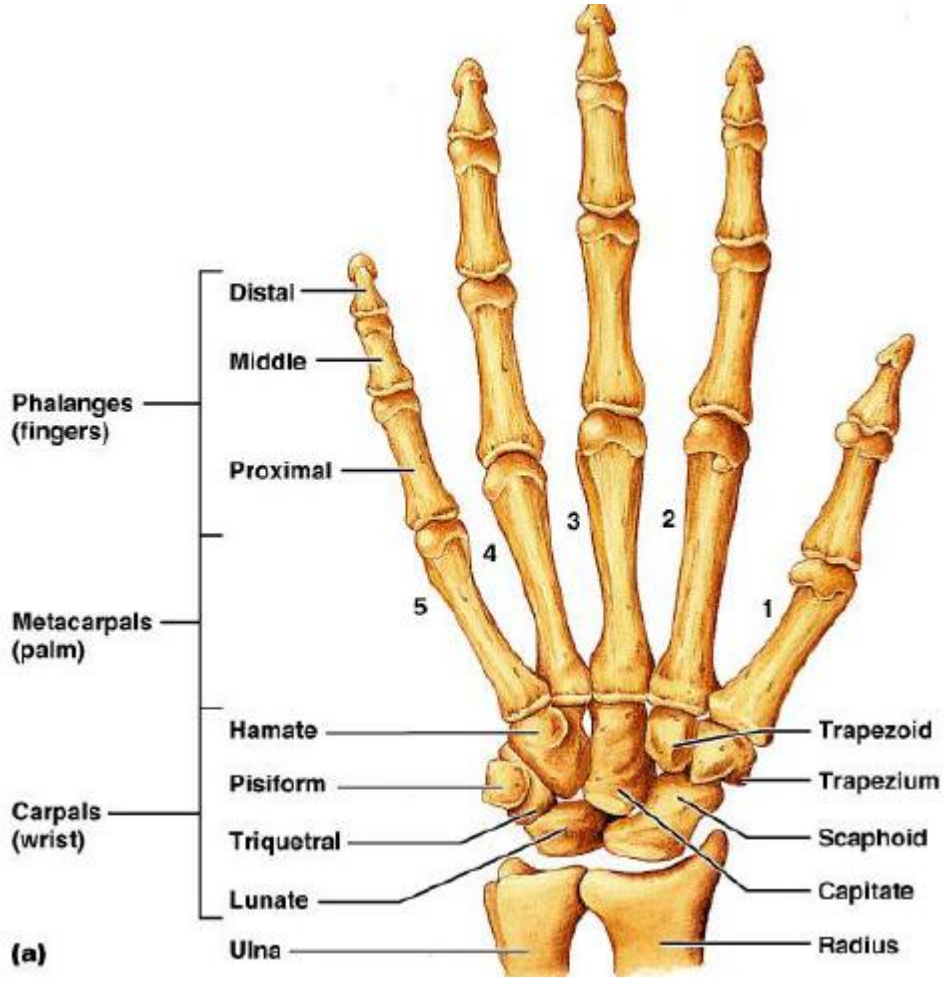

Pelvic Girdle

It is formed by the right and left coxal bones or hipbones join each other anteriorly and the sacrum posteriory.The pelvis includes the pelvic Girdle and coccyx.

The pelvis bear the weight of the body and also serves as the place of attachment for the lower limbs and protects the urinary bladder, the internal reproductive organs, and a portion of the large intestine.

Each **coxal bone** has the following three parts:

1. **ilium:** The ilium, the largest part of a coxal bone, flares outward to give the hip prominence. The margin of the ilium is called the iliac crest. Each ilium connects posteriorly with the sacrum at a **sacroiliac joint.**

2. **ischium:** The ischium is the most inferior part of a coxal bone. Its posterior region, the ischial tuberosity, allows a person to sit. Near the junction of the ilium and ischium is the **ischial spine,** which projects into the pelvic cavity. The distance between the ischial spines tells the size of the pelvic cavity. The **greater sciatic notch** is the site where blood vessels and the large sciatic nerve pass posteriorly into the lower leg.

3. **pubis:** The pubis is the anterior part of a coxal bone. The two pubic bones join together at the pubic symphysis. Posterior to where the pubis and the ischium join together is a large opening, the obturator foramen, through which blood vessels and nerves pass anteriorly into the leg.

Where the three parts of each coxal bone meet is a depression called the **acetabulum,** which receives the rounded head of the femur.

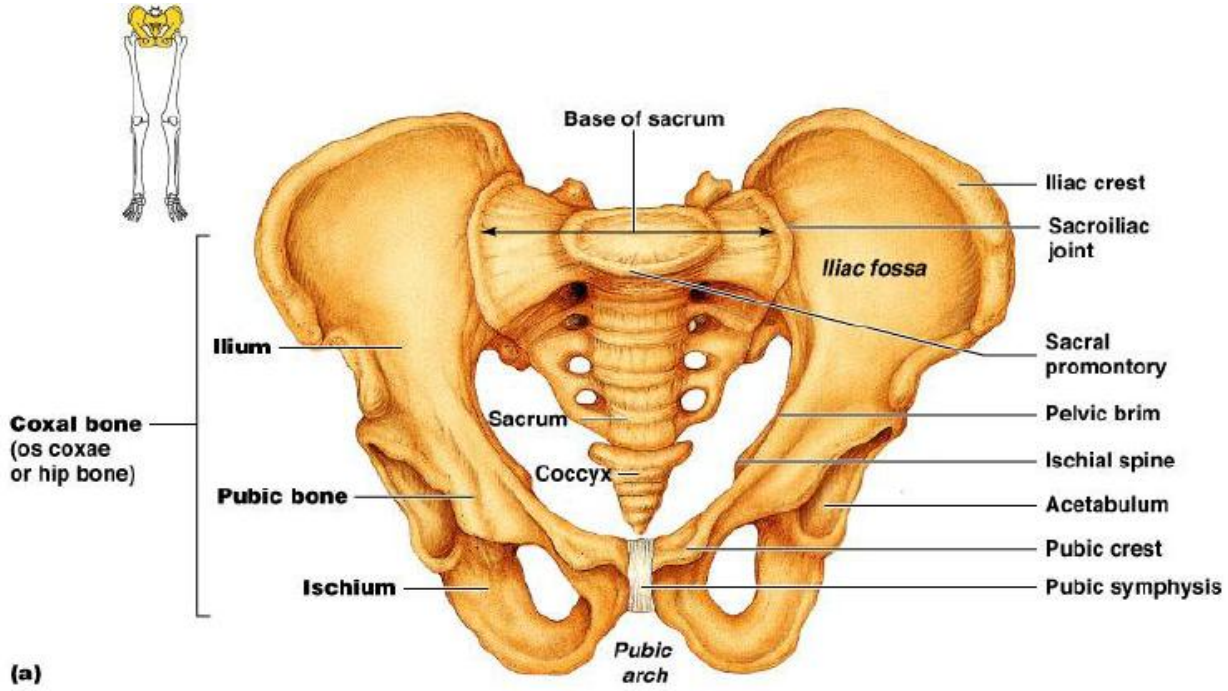

Lower Limb

The lower limb includes the bones of the thigh (femur), the kneecap (patella), the leg (tibia and fibula), and the foot (tarsals, metatarsals, and phalanges).

Femur

The **femur**: or thighbone, is the longest and strongest bone in the body.

Proximally, the femur has the following features:

Head, which fits into the acetabulum of the coxal bone;

Greater and **lesser trochanters,** which provide a place of attachment for the muscles of the thighs and buttocks;

Linea aspera, a crest that serves as a place of attachment for several muscles.

Distally, the femur has the following features:

Medial and **lateral epicondyles** that serve as sites of attachment for muscles and ligaments;

Lateral and **medial condyles** that articulate with the tibia;

Patellar surface, which is located between the condyles on the anterior surface, articulates with the **patella,** a small triangular bone that protects the knee joint.

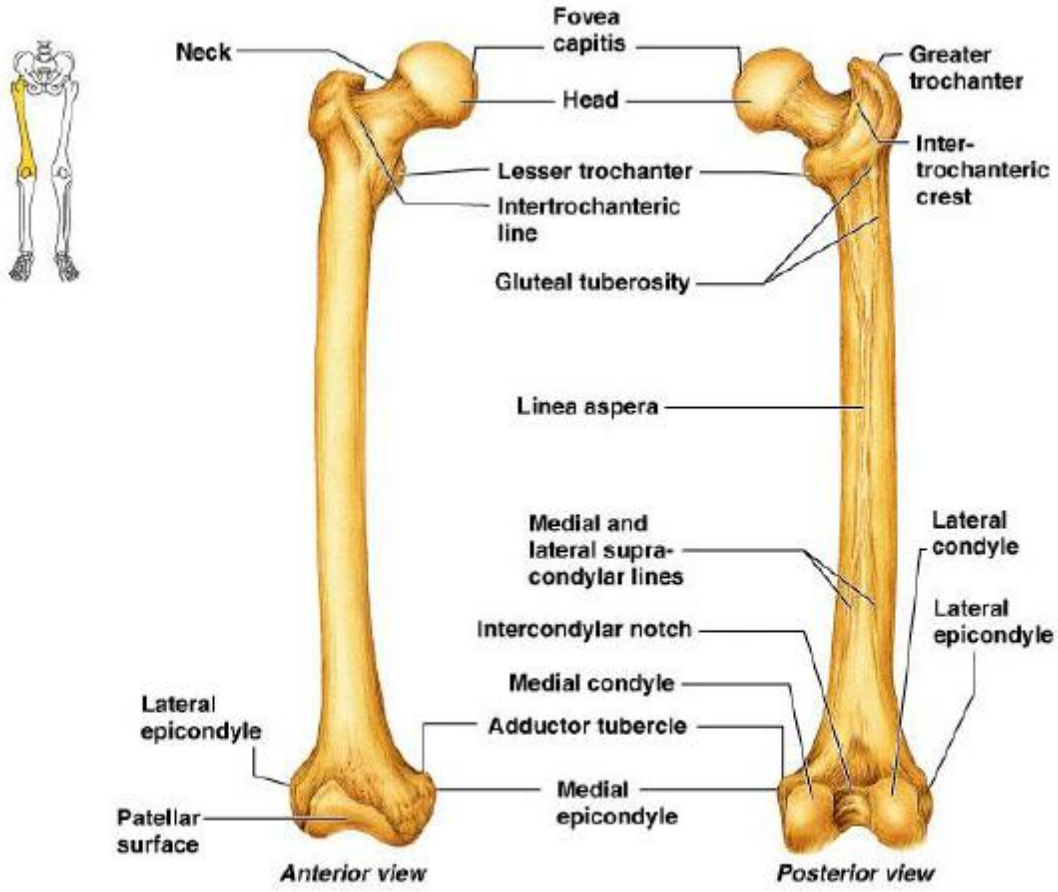

(b) Femur

Leg (tibia and fibula)

The **tibia** and **fibula** are the bones of the leg.

The **tibia**, or shinbone, is medial to the fibula. It is thicker than the fibula and bears the weight from the femur, with which it articulates.

It has the following features:

Medial and **lateral condyles,** which articulate with the femur;

Tibial tuberosity, where the patellar (kneecap) ligaments attach;

Anterior crest, commonly called the shin;

Medial malleolus, the bulge of the inner ankle, articulates with the talus in the foot.

The Fibula is lateral to the tibia and is more slender. It has a head that articulates with the tibia just below the lateral condyle. Distally, the **lateral malleolus** articulates with the talus and forms the outer bulge of the ankle. Its role is to stabilize the ankle.

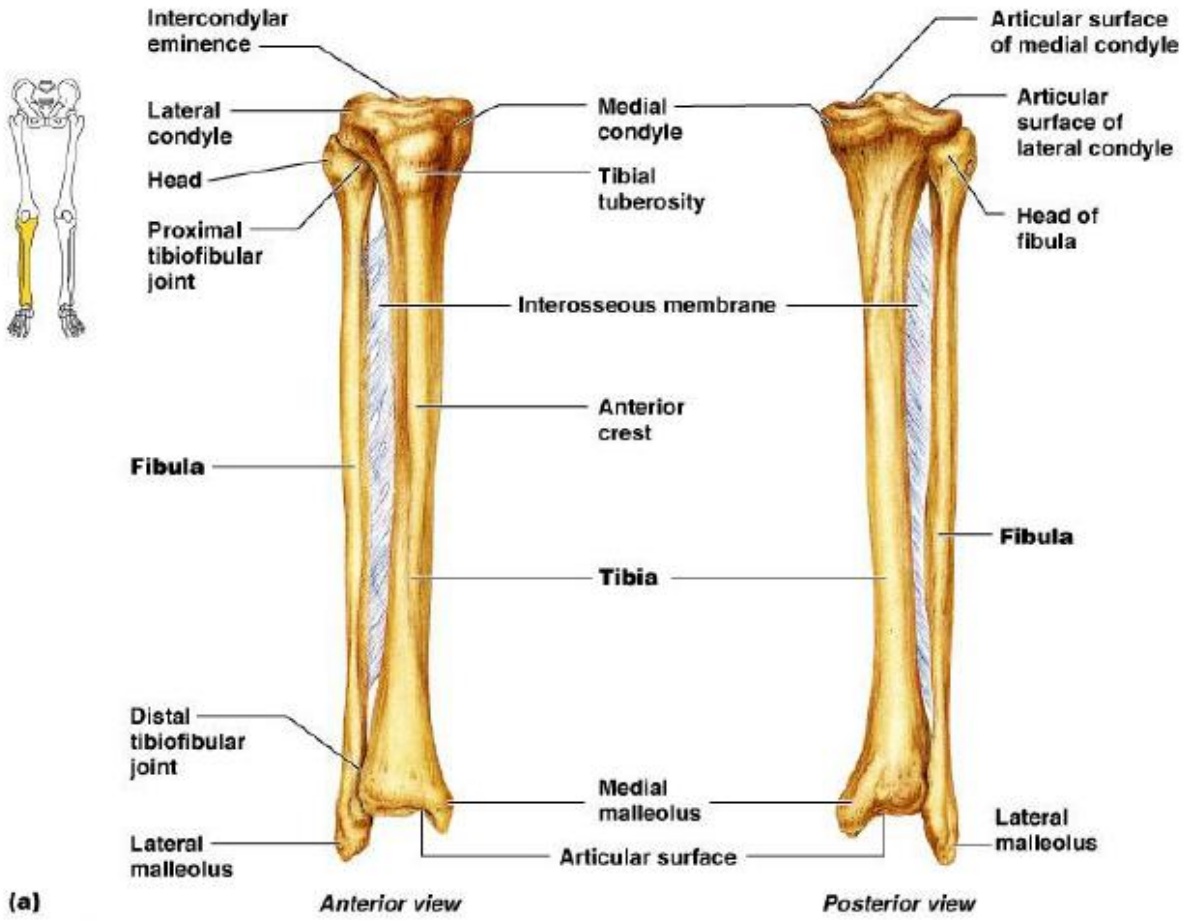

Foot

Each foot has an ankle, an instep, and five toes.

The ankle has seven **tarsal bones;** together, they are called the tarsus. Only one of the seven bones, the **talus,** can move freely where it joins the tibia and fibula. The largest of the ankle bones is the **calcaneus,** or heel bone. Along with the talus, it supports the weight of the body. **The navicular** lies between the talus posteriorly and the cuneiforms anteriorly. The talus, the calcaneus, and the navicular are proximal in the foot but do not form the row. The distal row is formed by **three cuneiforms (medial, intermediate, lateral)** and at its lateral by **the cuboid**.

The instep has five elongated **metatarsal bones.** The distal ends of the metatarsals form the ball of the foot. Along with the tarsals, these bones form the arches of the foot (longitudinal and transverse), which give spring to a person's walk.

The toes contain the **phalanges.** The big toe has only two phalanges, but the other toes have three each.

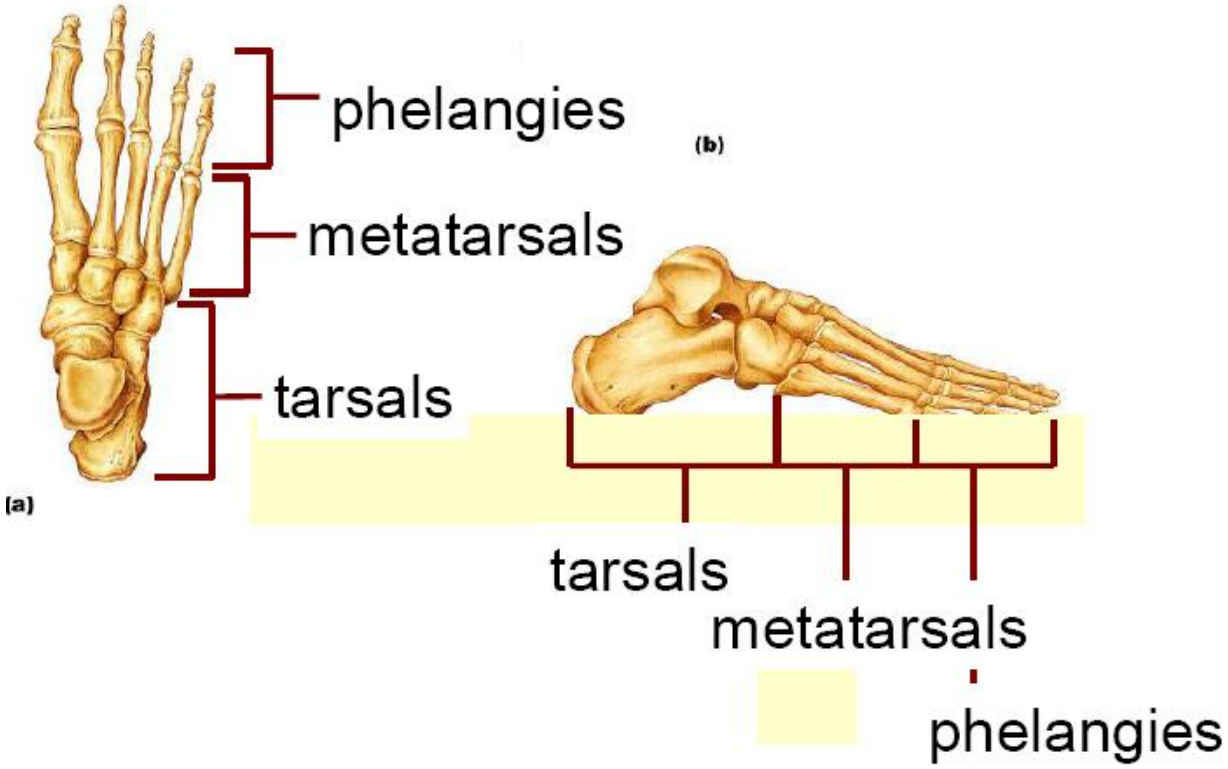

AGING AND THE SKELETAL SYSTEM

With age, bone tissue tends to lose more calcium than is replaced. Bone matrix becomes thinner, the bones themselves more brittle, and fractures are more likely to occur with mild trauma. Erosion of the articular cartilages of joints is also a common consequence of aging.

Joints affected include weight-bearing joints such as the knees, and active, small joints such as those of the fingers. Although the normal wear and tear of joints cannot be prevented, elderly people can preserve their bone matrix with exercise (dancing counts) and diets high in calcium and vitamin D.

4.1.8. Articulations

An articulation, or joint, is where two bones come together. In terms of the amount of movement they allow, there are three types of joints: immovable, slightly movable and freely movable.

- **Synarthroses**

Synarthroses are immovable joints. The singular form is synarthrosis. In these joints, the bones come in very close contact and are separated only by a thin layer of fibrous connective tissue. The sutures in the skull are examples of immovable joints.

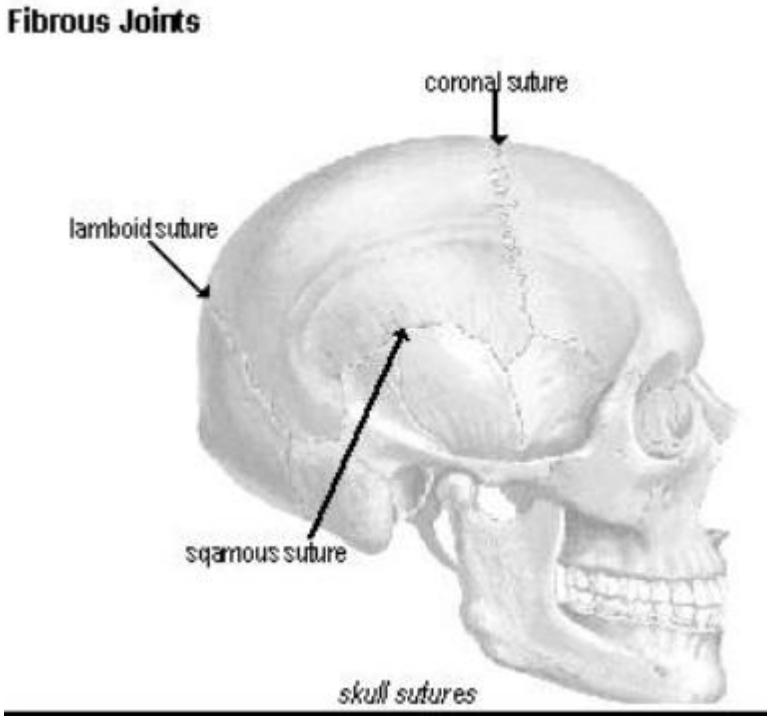

- **Amphiarthroses**

Slightly movable joints are called amphiarthroses. The singular form is amphiarthrosis. In this type of joint, the bones are connected by hyaline cartilage or fibrocartilage. The ribs connected to the sternum by costal cartilages are slightly movable joints connected by hyaline cartilage. The symphysis pubis is a slightly movable joint in which there is a fibrocartilage pad between the two bones. The joints between the vertebrae and the intervertebral disks are also of this type.

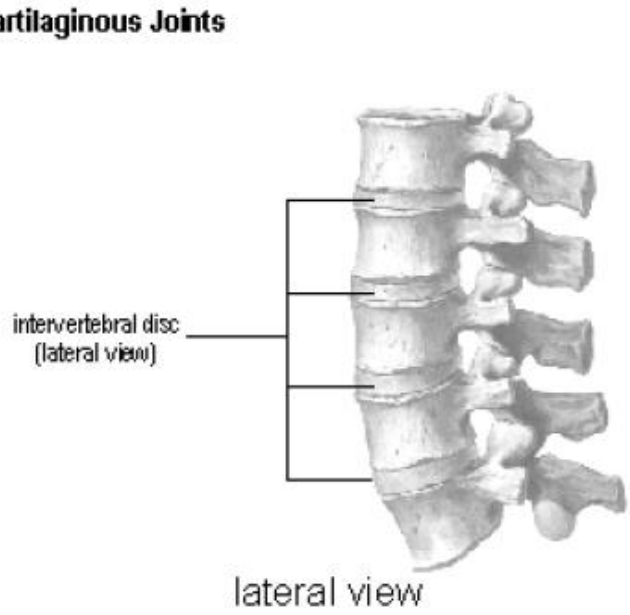

- **Diarthroses**

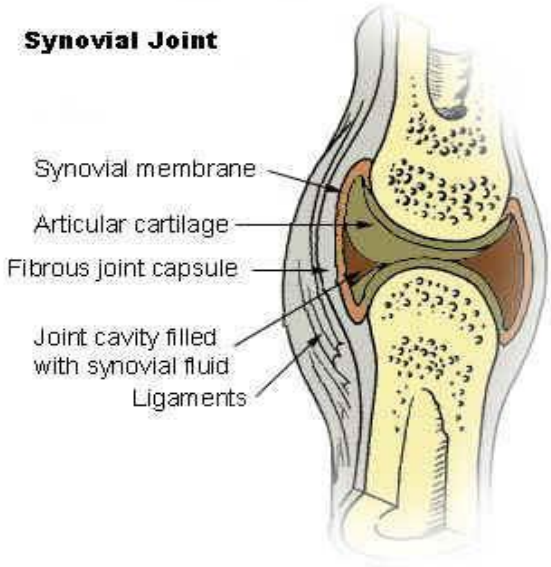

Most joints in the adult body are **diarthroses**, or freely movable joints. The singular form is **diarthrosis**. In this type of joint, the ends of the opposing bones are covered with **hyaline cartilage**, **the articular cartilage**, and they are separated by a space called the **joint cavity**. The components of the joints are enclosed in a dense fibrous **joint capsule**. The outer layer of the capsule consists of the **ligaments** that hold the bones together. The inner layer is the **synovial membrane** that secretes **synovial fluid** into the joint cavity for lubrication. Because all of these joints have a synovial membrane, they are sometimes called **synovial joints**.

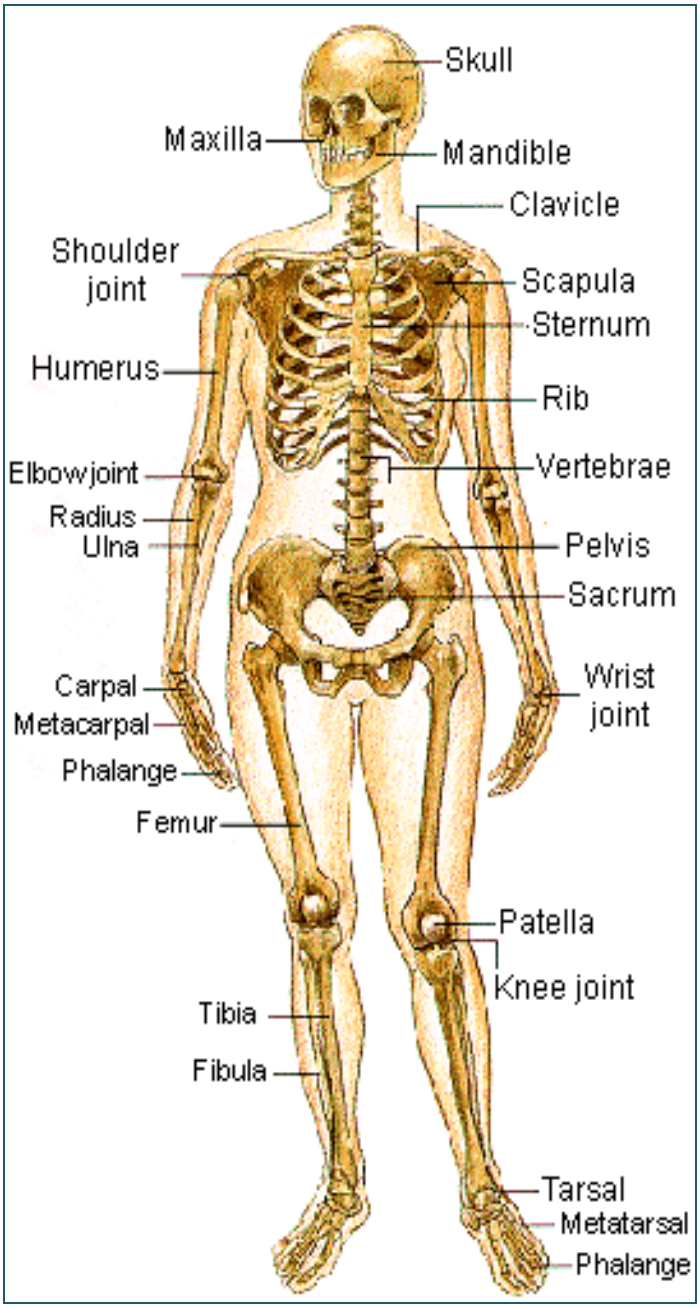

- **Applications to the nursing care**

1. FRACTURES AND THEIR REPAIR

A fracture means that a bone has been broken. There are different types of fractures classified as to extent of damage.

- ***Simple (closed)****:* the broken parts are still in normal anatomic position; surrounding tissue damage is minimal (skin is not pierced).
- ***Compound (open)****:* the broken end of a bone has been moved, and it pierces the skin; there may be extensive damage to

surrounding blood vessels, nerves, and muscles.

- ***Greenstick**:* the bone splits longitudinally. The bones of children contain more collagen than do adult bones and tend to splinter rather than break completely.
- ***Comminuted**:* two or more intersecting breaks create several bone fragments.
- **Impacted**: the broken ends of a bone are forced into one another; many bone fragments may be created.
- ***Pathologic (spontaneous)**:* a bone breaks without apparent trauma; may accompany bone disorderssuch as osteoporosis.

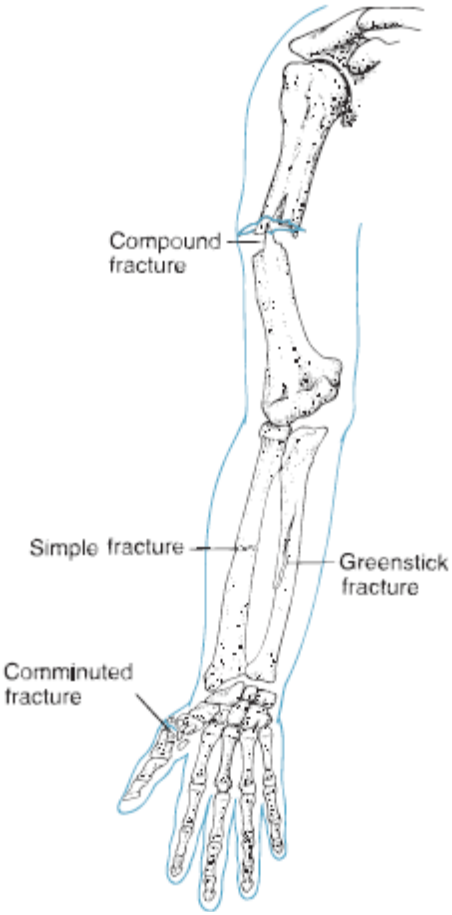

2. THE REPAIR PROCESS

Even a simple fracture involves significant bone damage that must be repaired if the bone is to resume its normal function. Fragments of dead or damaged bone must first be removed. This is accomplished by osteoclasts, which dissolve and reabsorb the calcium salts of bone matrix. Imagine a building that has just collapsed; the rubble must be removed before reconstruction can take place. This is what the osteoclasts do. Then, new bone must be produced.

The inner layer of the periosteum contains osteoblasts that are activated when bone is damaged. The osteoblasts produce bone matrix to knit the broken ends of the bone together.Because most bone has a good blood supply, the repair process is usually relatively rapid, and a simplefracture often heals within 6 weeks. Some parts of bones, however, have a poor blood supply, and repair of fractures takes longer. These areas are the neck of the femur (the site of a “fractured hip”) and the lower third of the tibia.Other factors that influence repair include the age of the person, general state of health, and nutrition. The elderly and those in poor health often have slow heal-

ing of fractures. A diet with sufficient calcium, phosphorus, vitamin D, and protein is also important. If any of these nutrients is lacking, bone repair will be a slower process.

3. OSTEOPOROSIS

Bone is an active tissue; calcium is constantly being removed to maintain normal blood calcium levels. Usually, however, calcium is replaced in bones at a rate equal to its removal, and the bone matrix remains strong.

Osteoporosis is characterized by excessive loss of calcium from bones without sufficient replacement. Research has suggested that a certain gene for bone buildup in youth is an important factor; less buildup would mean earlier bone thinning. Contributing environmental factors include smoking, insufficient dietary intake of calcium, inactivity, and lack of the sex hormones. Osteoporosis is most common among elderly women, because estrogen secretion decreases sharply at menopause (in older men, testosterone is still secreted in significant amounts). Factors such as bed rest or inability to get even minimal exercise will make calcium loss even more rapid.

As bones lose calcium and become thin and brittle, fractures are much more likely to occur. Among elderly women, a fractured hip (the neck of the femur) is an all-too-common consequence of this degenerative bone disorder. Such a serious injury is not inevitable, however, and neither is the thinning of the vertebrae that bows the spines of some elderly people. After menopause, women may wish to have a bone density test to determine the strength of their bone matrix. Several medications are available that diminish the rate of bone loss. A diet high in calcium and vitamin D is essential for both men and women, as is moderate exercise. Young women and teenagers should make sure they get adequate dietary calcium to form strong bone matrix, because this will delay the serious effects of osteoporosis later in life.

4. HERNIATED DISC

The vertebrae are separated by discs of fibrous cartilage that act as cushions to absorb shock. An intervertebral disc has a tough outer covering and a soft center called the nucleus pulposus. Extreme pressure on a disc may rupture the outer layer and force the nucleus pulposus out. This may occur when a person lifts a heavy object improperly, that is, using the back rather than the

legs and jerking upward, which puts sudden, intense pressure on the spine. Most often this affects discs in the lumbar region. Although often called a "slipped disc," the affected disc is usually not moved out of position.

The terms **herniated disc** or **ruptured disc** more accurately describe what happens. The nucleus pulposus is forced out, often posteriorly, where it puts pressure on a spinal nerve. For this reason a herniated disc may be very painful or impair function in the muscles supplied by the nerve.Healing of a herniated disc may occur naturally if the damage is not severe and the person rests and avoids activities that would further compress the disc. Surgery may be required, however, to remove the portion of the nucleus pulposus that is out of place and disrupting nerve functioning.

5. ABNORMALITIES OF THE CURVES OF THE SPINE

Scoliosis*:* an abnormal lateral curvature, which may be congenital, the result of having one leg longer than the other, or the result of chronic poor posture during childhood while the vertebrae are still growing. Usually the thoracic vertebrae are affected, which displaces the rib cage to one side. In severe cases, the abdominal organs may be compressed, and the expansion of the rib cage during inhalation may be impaired.

Kyphosis*:* an exaggerated thoracic curve; sometimes referred to as hunchback.

Lordosis: an exaggerated lumbar curve; sometimes referred to as swayback.

These abnormal curves are usually the result of degenerative bone diseases such as osteoporosis or tuberculosis of the spine. If osteoporosis, for example, causes the bodies of the thoracic vertebrae to collapse, the normal thoracic curve will be increased. Most often the vertebral body "settles" slowly (rather than collapses suddenly) and there is little, if any, damage to the spinal nerves. The damage to the vertebrae, however, cannot be easily corrected, so these conditions should be thought of in terms of prevention rather than cure.

6. ARTHRITIS

The term **arthritis** means "inflammation of a joint." Of the many types of arthritis, we will consider two: osteoarthritis and rheumatoid arthritis.

Osteoarthritis is a natural consequence of getting older. In joints that have borne weight for many years, the articular cartilage is gradually worn away. The once smooth joint surface becomes rough, and the affected joint is stiff and painful. As you might guess, the large, weight-bearing joints are most often subjected to this form of arthritis. If we live long enough, most of us can expect some osteoarthritis in knees, hips, or ankles.

Rheumatoid arthritis (RA) can be a truly crippling disease that may begin in early middle age or, less commonly, during adolescence. It is an **autoimmune disease**, which means that the immune system mistakenly directs its destructive capability against part of the body. Exactly what triggers this abnormal response by the immune system is not known with certainty, but certain bacterial and viral infections have been suggested as possibilities. Rheumatoid arthritis often begins in joints of the extremities, such as those of the fingers. The autoimmune activity seems to affect the synovial membrane, and joints become painful and stiff. Sometimes the disease progresses to total destruction of the synovial membrane and calcification of the joint. Such a joint is then fused and has no mobility at all. Autoimmune damage may also occur in the heart and blood vessels, and those with RA are more prone to heart attacks and strokes (RA is a systemic, not a localized, disease).Treatment of rheumatoid arthritis is directed at reducing inflammation as much as possible, for it is the inflammatory process that causes the damage. Therapies being investigated involve selectively blocking specific aspects of the immune response, such as antibody production. At present there is no cure for autoimmune diseases.

4.2. MUSCULAR SYSTEM

4.2.1. Functions of the Muscular System

- **Body movement**: most skeletal muscles are attached to bones, are typically under conscious control, and are responsible for most body movement, including walking, running, and manipulating objects with the hands.
- **Maintenance of posture**: Skeletal muscles constantly maintain tone, which keep us sitting or standing erect.

- **Respiration**: Skeletal muscles of the thorax are responsible for movement necessary for respiration.
- **Production of body heat:** The contraction of skeletal muscles produces body heat. This released heat is critical to the maintenance of body temperature. Nearly 85 percent of the heat produced in the body is the result of muscle contraction.
- **Communication:** skeletal muscles are involved in all aspects of communication, such us speaking, writing, typing, gesturing, facial expression.
- **Construction of organs and vessels:** The contraction of smooth muscles within the wall of intestinals organs and vessels causes constriction of those structures. This constriction can help propel and mix food and water in the digestive tract, propel secretions from organs, and regulate blood flow through vessels.
- **Heart beat.** The contractin of cardiac muscles causes the heart to beat, propelling blood to all parts of the body.

4.2.2 Muscle Types

In the body, there are three types of muscle: skeletal (striated), smooth, and cardiac.

a. Skeletal Muscle

Skeletal muscle, attached to bones, is responsible for skeletal movements. The peripheral portion of the central nervous system (CNS) controls the skeletal muscles. Thus, these muscles are under conscious, or voluntary, control. The basic unit is the muscle fiber with many nuclei. These muscle fibers are striated (having transverse streaks) and each acts independently of neighboring muscle fibers.

b. Smooth Muscle

Smooth muscle, found in the walls of the hollow internal organs such as blood vessels, the gastrointestinal tract, bladder, and uterus, is under control of the autonomic nervous system. Smooth muscle cannot be controlled consciously and thus acts involuntarily. The non-striated (smooth) muscle cell is spindle-shaped and has one central nucleus. Smooth muscle contracts and relaxes slowly and rhythmically, produces peristalsis; may sustain contraction.

c. Cardiac Muscle

Cardiac muscle, found in the walls of the heart, pumps blood out of heart and is also under control of the autonomic nervous system. The cardiac muscle cell has one central nucleus, like smooth muscle. The cardiac muscle cell is rectangular in shape. The contraction of cardiac muscle is involuntary, strong, and rhythmical.

4.2.3. Properties of muscles

Muscles have four major functional properties: contractility, excitability, extensibility, and elasticity.

- **Contractility:** is the ability of muscles to shorten forcefully. When muscle contracts, it causes movement of the structures to which it is attached, it may increase pressure inside hollow organs or vessels.
- **Excitability:** is the capacity of muscle to respond to a stimulus. Normally, skeletal muscle contracts as a result of stimulation by nerves; smooth muscle and cardiac muscle can contract without outside stimulus, but they also respond to stimulation by nerves and hormones.
- **Extensibility:** means that muscle can be stretched (extended) beyond its normal resting length and is still able to contract.
- **Elasticity:** is the ability of muscles to recoil to its original resting length after it has been stretched**.**

4.2.4. Structure of Skeletal Muscle

A whole skeletal muscle is considered an organ of the muscular system. Each organ or muscle consists of skeletal muscle tissue, connective tissue, nerve tissue, and blood or vascular tissue.

Skeletal muscles vary considerably in size, shape, and arrangement of fibers. They range from extremely tiny strands such as the stapedium muscle of the middle ear to large masses such as the muscles of the thigh. Some skeletal muscles are broad in shape and some narrow. In some

muscles the fibers are parallel to the long axis of the muscle, in some they converge to a narrow attachment, and in some they are oblique.

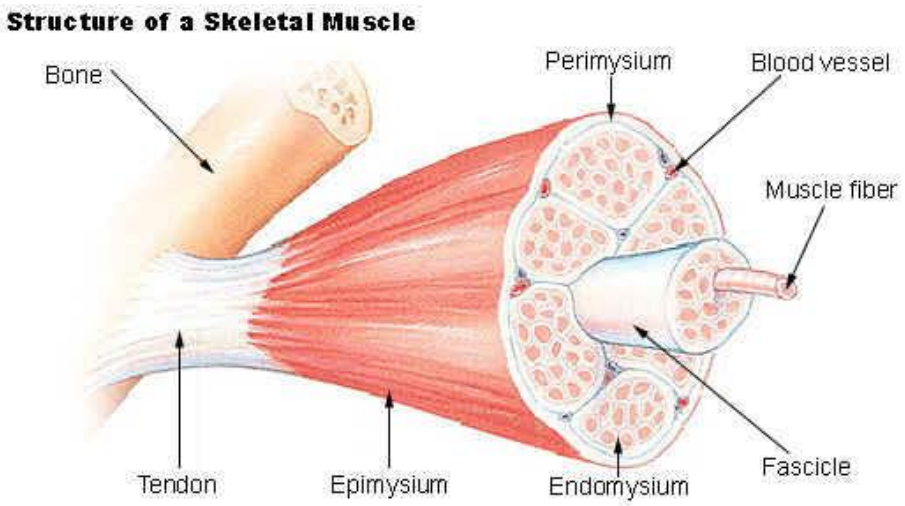

Each skeletal muscle fiber is a single cylindrical muscle cell. An individual skeletal muscle may be made up of hundreds, or even thousands, of muscle fibers bundled together and wrapped in a connective tissue covering. Each muscle is surrounded by a connective tissue sheath called the epimysium. Fascia, connective tissue outside the epimysium, surrounds and separates the muscles. Portions of the epimysium project inward to divide the muscle into compartments. Each compartment contains a bundle of muscle fibers. Each bundle of muscle fiber is called a fasciculus and is surrounded by a layer of connective tissue called the perimysium. Within the fasciculus, each individual muscle cell, called a muscle fiber, is surrounded by connective tissue called the endomysium.

Skeletal muscle cells (fibers), like other body cells, are soft and fragile. The connective tissue covering furnish support and protection for the delicate cells and allow them to withstand the forces of contraction. The coverings also provide pathways for the passage of blood vessels and nerves.

Commonly, the epimysium, perimysium, and endomysium extend beyond the fleshy part of the muscle, to form a thick ropelike tendon or a broad, flat sheet-like aponeurosis. The tendon and aponeurosis form indirect attachments from muscles to the periosteum of bones or to the connective tissue of other muscles. Typically a muscle spans a joint and is attached to bones by

tendons at both ends. One of the bones remains relatively fixed or stable while the other end moves as a result of muscle contraction.

Skeletal muscles have an abundant supply of blood vessels and nerves. This is directly related to the primary function of skeletal muscle, contraction. Before a skeletal muscle fiber can contract, it has to receive an impulse from a nerve cell. Generally, an artery and at least one vein accompany each nerve that penetrates the epimysium of a skeletal muscle. Branches of the nerve and blood vessels follow the connective tissue components of the muscle of a nerve cell and with one or more minute blood vessels called capillaries.

MICROSCOPIC ANATOMY AND CONTRACTION OF SKELETAL MUSCLE

We have already examined the structure of skeletal muscle as seen with the light microscope. As you know, skeletal muscle tissue has alternating light and dark bands, giving it a striated appearance. The electron microscope shows that these bands are due to the arrangement of myofilaments in a muscle fiber.

Muscle Fiber

A muscle fiber contains the usual cellular components, but special names have been assigned to some of these components

The plasma membrane is called the *sarcolemma*; the cytoplasm is the sarcoplasm; and the endoplasmic reticulum is the *sarcoplasmic reticulum***.**

A muscle fiber also has some unique anatomical characteristics.

One feature is its T (for transverse) system; the sarcolemma forms **T (transverse) tubules** that penetrate, or dip down, into the cell so that they come into contact but do not fuse with expanded portions of the sarcoplasmic reticulum.

The expanded portions of the sarcoplasmic reticulum are calcium storage sites. Calcium ions (Ca2_), as we shall see, are essential for muscle contraction.

The sarcoplasmic reticulum encases hundreds and sometimes even thousands of **myofibrils,** each about 1 _m in diameter**,** which are the contractile portions of the muscle fibers. Any other organelles, such as mitochondria, are located in the sarcoplasm between the myofibrils.

The sarcoplasm also contains glycogen, which provides stored energy for muscle contraction, and the red pigment **myoglobin,** which binds oxygen until it is needed for muscle contraction.

Myofibrils and Sarcomeres

Myofibrils are cylindrical in shape and run the length of the muscle fiber. The striations of skeletal muscle fibers are formed by the placement of myofilaments within units of myofibrils called **sarcomeres.** A sarcomere extends between two dark lines called the Z lines. A sarcomere contains two types of protein myofilaments. The thick filaments are made up of a protein called **myosin,** and the thin filaments are made up of a protein called **actin.** Other proteins are also present. The I band is light colored because it contains only actin filaments attached to a Z line. The dark regions of the A band contain overlapping actin and myosin filaments, and its H zone has only myosin filaments.

Myofilaments

The thick and thin filaments differ in the following ways:

- **Thick Filaments:** A thick filament is composed of several hundred molecules of the protein myosin. Each myosin molecule is shaped like a golf club, with the straight portion of the molecule ending in a double globular head, or *crossbridge*.
  Cross-bridges are slanted away from the middle of a sarcomere.
- **Thin Filaments:** Primarily, a thin filament consists of two intertwining strands of the protein actin. Two other proteins, called tropomyosin and troponin, are also present, as we will discuss later in this section.
- **Sliding Filaments:** We will also see that when muscles are innervated, impulses travel down a T tubule, and calcium is released from the sarcoplasmic reticulum. Now the muscle fiber contracts as the sarcomeres within the myofibrils shorten. When a sarcomere shortens, the actin (thin) filaments slide past the myosin (thick) filaments and approach one another. This causes the I band to shorten and the H zone to almost or completely disappear. The movement of actin filaments in relation to myosin filaments is called the **sliding filament theory** of muscle contraction. During the sliding process, the sarcomere shortens even though the filaments themselves remain the same length. ATP supplies the energy for muscle contraction. Although the actin filaments slide past the

myosin filaments, it is the myosin filaments that do the work. Myosin filaments break down ATP and have crossbridges that pull the actin filaments toward the center of the sarcomere.

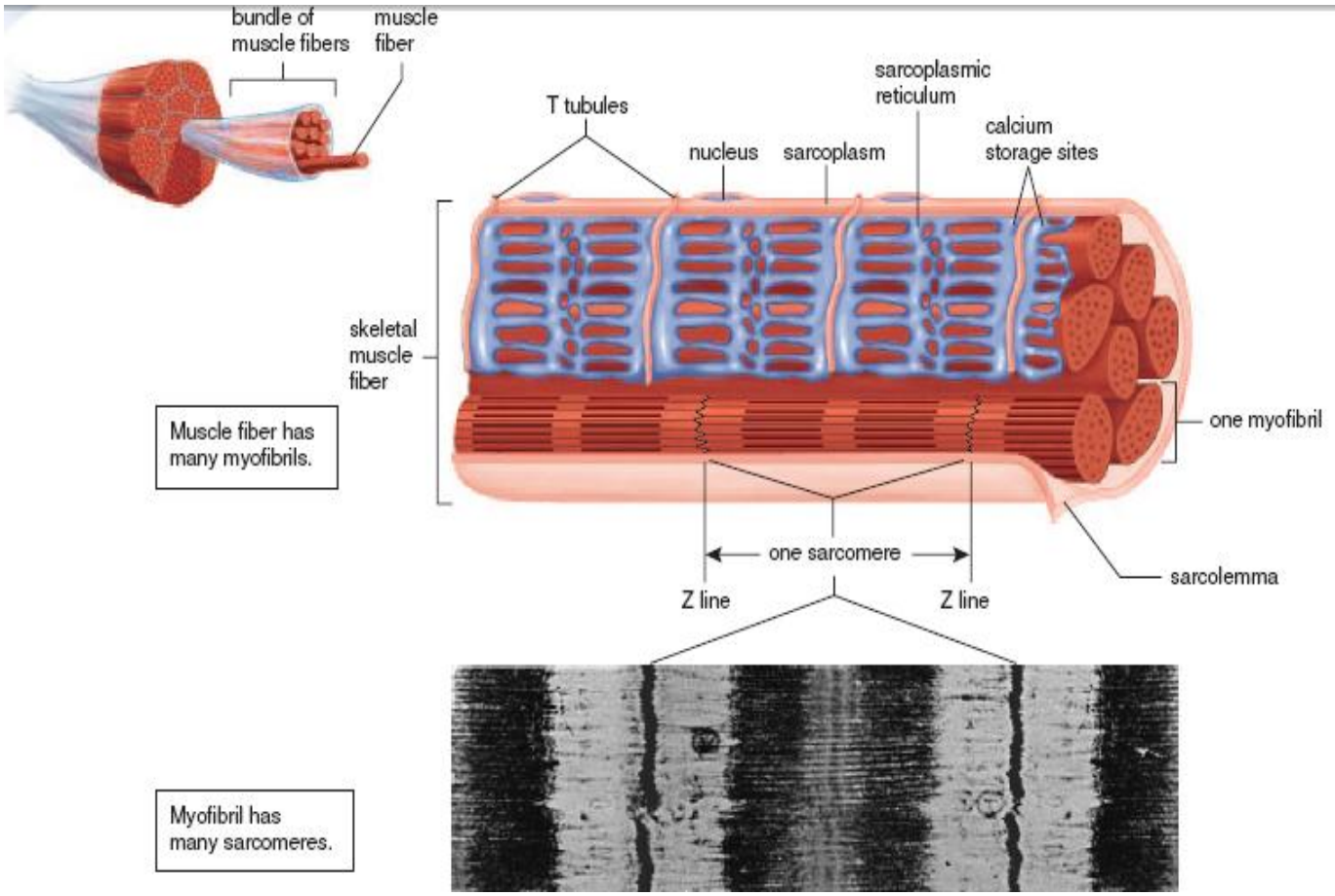

Anatomy of a muscle fiber

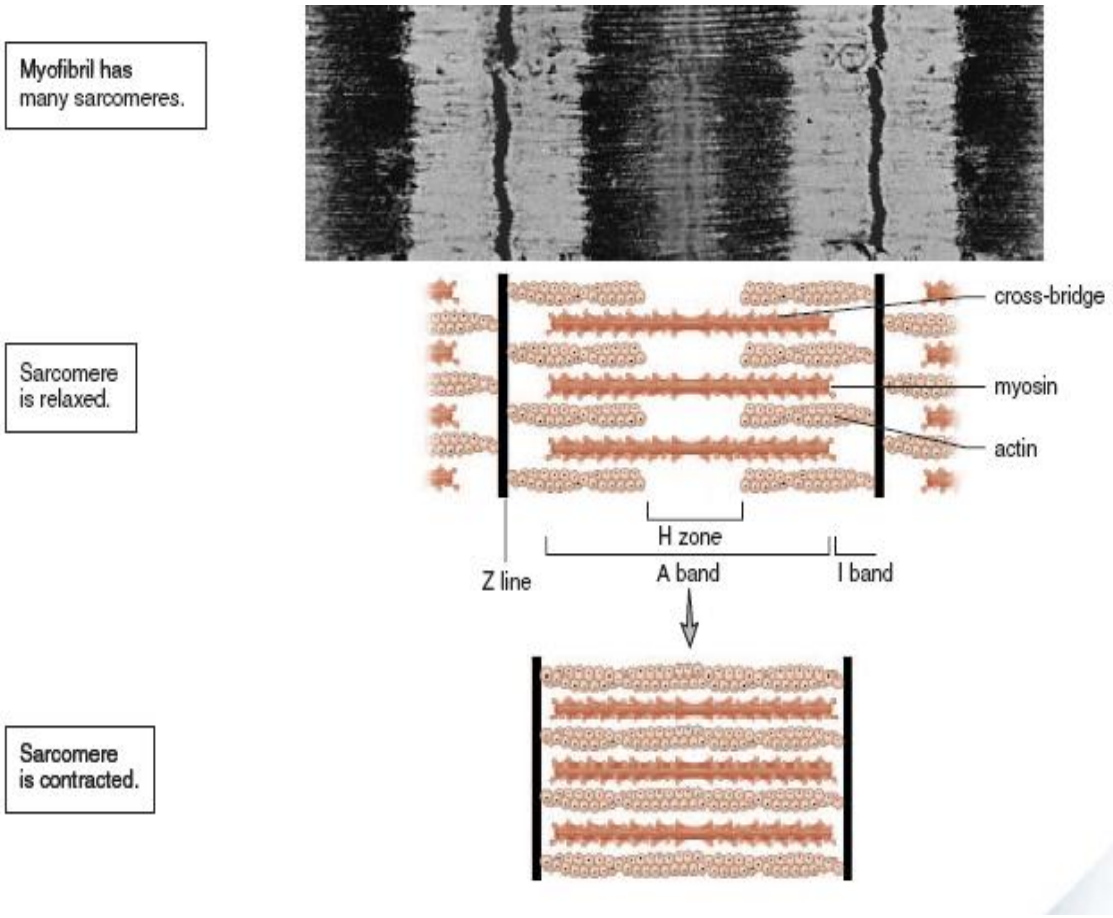

Anatomy of a muscle fiber

Skeletal Muscle Contraction

Muscle fibers are innervated; they are stimulated to contract by motor neurons whose axons are found in nerves.

The axon of one motor neuron has several branches and can stimulate from a few to several muscle fibers of a particular muscle. Each branch of the axon ends in an axon terminal that lies in close proximity to the sarcolemma of a muscle fiber. A small gap, called a synaptic cleft, separates the axon bulb from the sarcolemma. This entire region is called a **neuromuscular junction.**

Axon terminals contain synaptic vesicles that are filled with the neurotransmitter acetylcholine (ACh). When nerve impulses traveling down a motor neuron arrive at an axon terminal, the synaptic vesicles release a neurotransmitter into the synaptic cleft. It quickly diffuses across the cleft and binds to receptors in the sarcolemma. Now the sarcolemma generates impulses that

spread over the sarcolemma and down T tubules to the sarcoplasmic reticulum. The release of calcium from the sarcoplasmic reticulum causes the filaments within the sarcomeres to slide past one another. Sarcomere contraction results in myofibril contraction, which in turn results in muscle fiber, and finally muscle, contraction.

Neuromuscular junction

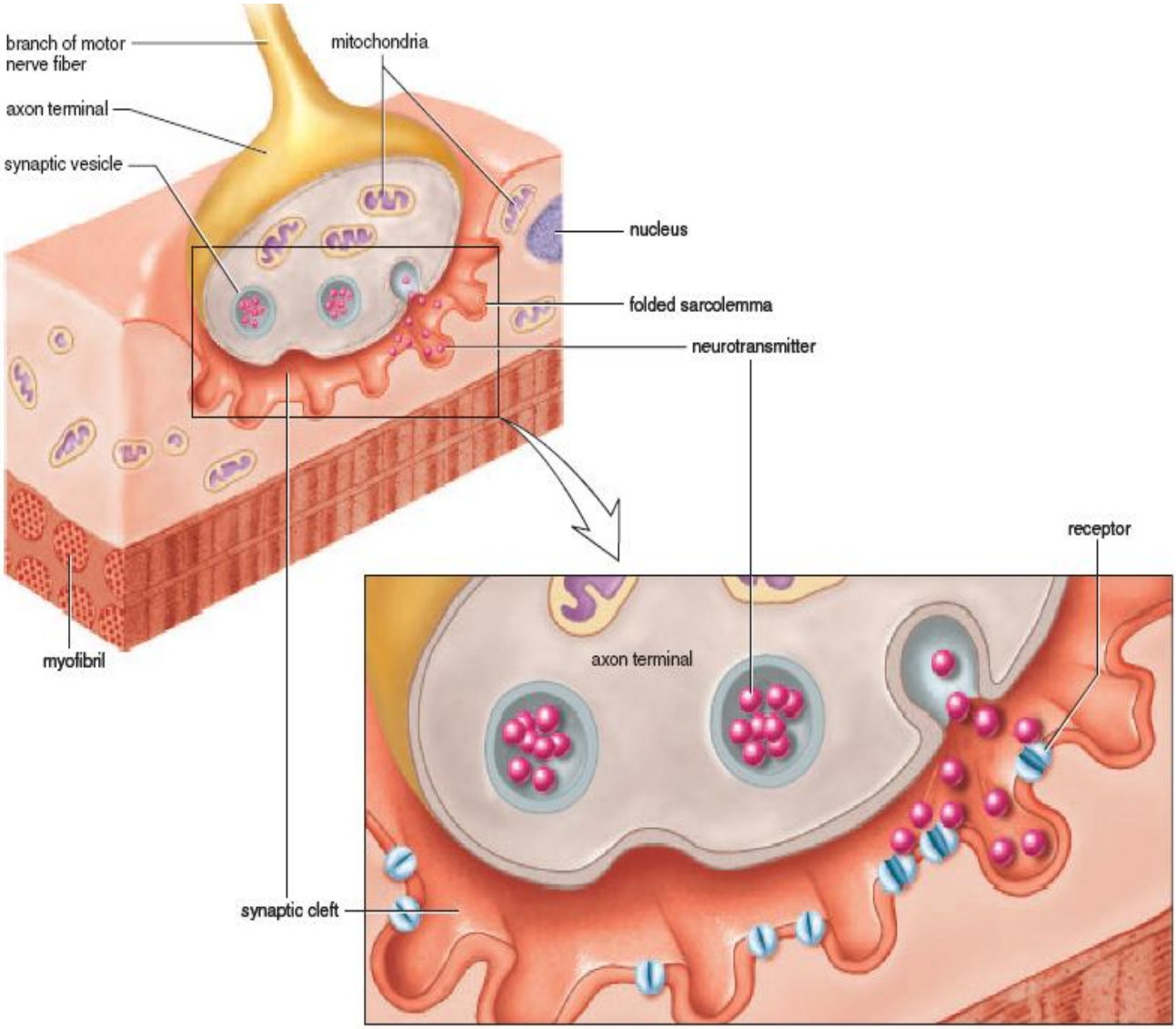

***Figure**: The branch of an axon ends in an axon terminal that meets but does not touch a muscle fiber. A synaptic cleft separates the axon terminal from the sarcolemma of the muscle fiber. Nerve impulses traveling down an axon cause synaptic vesicles to discharge acetylcholine, which diffuses across the synaptic cleft. When the neurotransmitter is received by the sarcolemma of a muscle fiber, impulses begin and lead to muscle fiber contractions.*

The Role of Actin and Myosin

Shows the placement of two other proteins associated with an actin filament, which you will recall is composed of a double row of twisted actin molecules. Threads of *tropomyosin* wind about an actin filament, and *troponin* occurs at intervals along the threads. Calcium ions ($Ca2^{+}$) that have been released from the sarcoplasmic reticulum combine with troponin. After binding occurs, the tropomyosin threads shift their position, and myosin binding sites are exposed.

The double globular heads of a myosin filament have ATP binding sites. The heads function as ATPase enzymes, splitting ATP into ADP and _P.

This reaction activates the head so that it will bind to actin. The ADP and _P remains onthe myosin heads until the heads attach to actin, forming a cross-bridge. Now, ADP and _P are released, and this causes the cross-bridges to change their positions. This is the power stroke that pulls the thin filaments toward the middle of the sarcomere. When another ATP molecule binds to a myosin head, the cross-bridge is broken as the head detaches from actin. The cycle begins again; the actin filaments move nearer the center of the sarcomere each time the cycle is repeated.

Contraction continues until nerve impulses cease and calcium ions are returned to their storage sites. The membranes of the sarcoplasmic reticulum contain active transport proteins that pump calcium ions back into the sarcoplasmic reticulum.

The Contraction Cycle

At the onset of contraction, the sarcoplasmic reticulum releases calcium ions (Ca^{2+}) into the cytosol. There, they bind to troponin.

Troponin then moves tropomyosin away from the myosinbinding sites on actin. Once the binding sites are “free,” the **contraction cycle**—the repeating sequence of events that causes the filaments to slide begins. The contraction cycle consists of four steps:

●**1*ATP hydrolysis:*** The myosin head includes an ATP-binding site and an ATPase, an enzyme that hydrolyzes ATP into ADP (adenosine diphosphate) and a phosphate group. This hydrolysis reaction reorients and energizes the myosin head.

Notice that the products of ATP hydrolysis—ADP and a phosphate group—are still attached to the myosin head.

●**2** ***Attachment of myosin to actin to form crossbridges:*** The energized myosin head attaches to the myosin-binding site on actin and releases the previously hydrolyzed phosphate group. When the myosin heads attach to actin during contraction, they are referred to as **crossbridges.**

●**3** ***Power stroke:*** After the crossbridges form, the power stroke occurs. During the power stroke, the site on the crossbridge where ADP is still bound opens. As a result, the crossbridge rotates and releases the ADP. The crossbridge generates force as it rotates toward the center of the sarcomere, sliding the thin filament past the thick filament toward the M line.

●**4** ***Detachment of myosin from actin:*** At the end of the power stroke, the crossbridge remains firmly attached to actin until it binds another molecule of ATP. As ATP binds to the ATPbinding site on the myosin head, the myosin head detaches from actin.

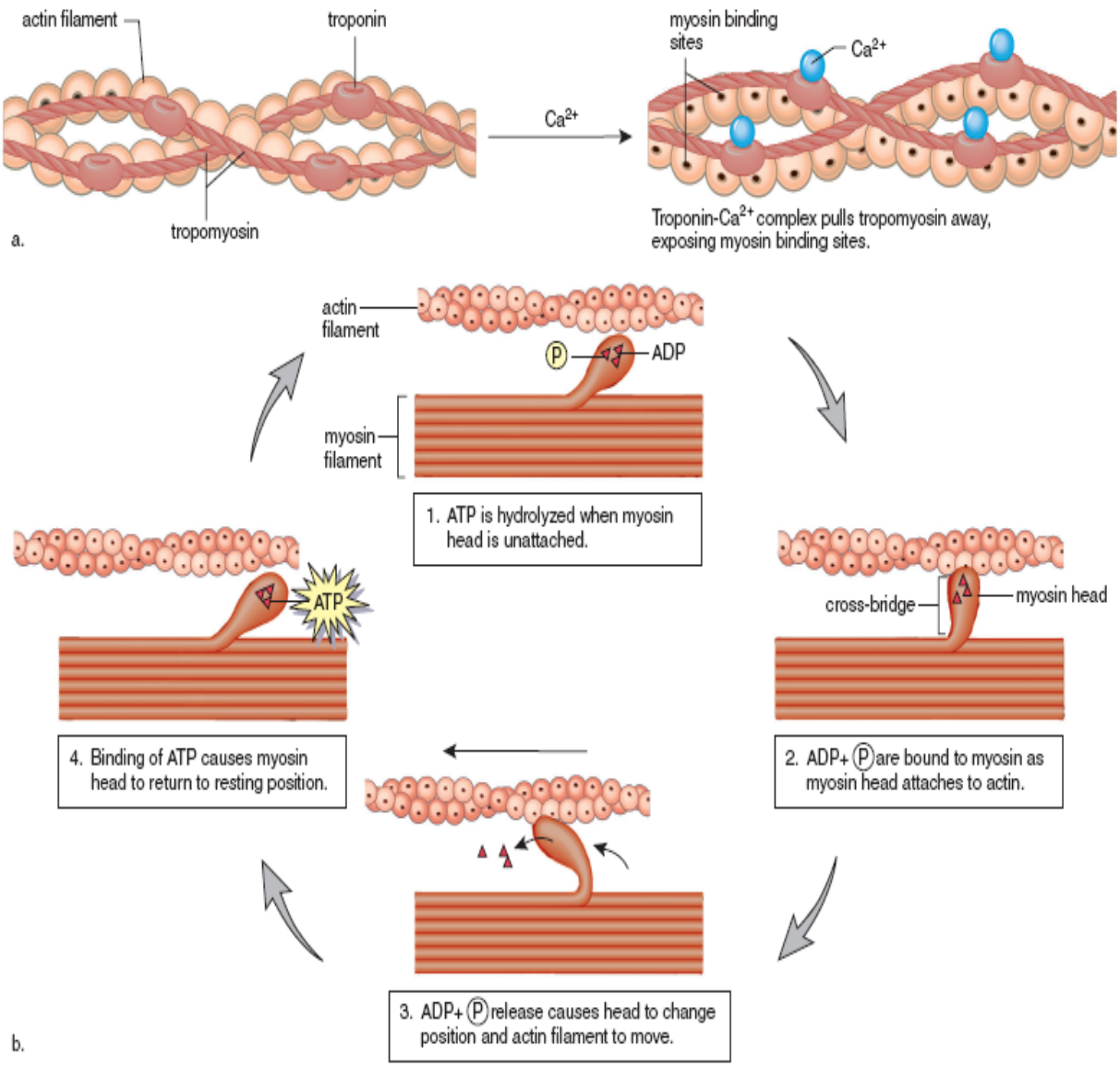

Energy for Muscle Contraction

ATP produced previous to strenuous exercise lasts a few seconds, and then muscles acquire new ATP in three different ways: creatine phosphate breakdown, cellular respiration, and fermentation.

Creatine phosphate breakdown and fermentation are anaerobic, meaning that they do not require oxygen.

Creatine Phosphate Breakdown

Creatine phosphate is a high-energy compound built up when a muscle is resting. Creatine phosphate cannot participate directly in muscle contraction. Instead, it can regenerate
ATP by the following reaction:

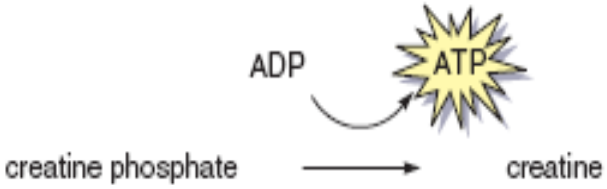

This reaction occurs in the midst of sliding filaments, and therefore is the speediest way to make ATP available to muscles.

Creatine phosphate provides enough energy for only about eight seconds of intense activity, and then it is spent.

Creatine phosphate is rebuilt when a muscle is resting by transferring a phosphate group from ATP to creatine.

Cellular Respiration

Cellular respiration completed in mitochondria usually provides most of a muscle's ATP. Glycogen and fat are stored in muscle cells. Therefore, a muscle cell can use glucose from glycogen and fatty acids from fat as fuel to produce ATP if oxygen is available:

Myoglobin, an oxygen carrier similar to hemoglobin, is synthesized in muscle cells, and its presence accounts for the reddish-brown color of skeletal muscle fibers. Myoglobin has a higher affinity for oxygen than does hemoglobin.

Therefore, myoglobin can pull oxygen out of blood and make it available to muscle mitochondria that are carrying on cellular respiration. Then, too, the ability of myoglobin to temporarily store oxygen reduces a muscle's immediate need for oxygen when cellular respiration begins. The endproducts (carbon dioxide and water) are usually no problem.

Carbon dioxide leaves the body at the lungs, and water simply enters the extracellular space. The by-product, heat, keeps the entire body warm.

Fermentation

Fermentation, like creatine phosphate breakdown, supplies ATP without consuming oxygen. During fermentation, glucose is broken down to lactate (lactic acid):

The accumulation of lactate in a muscle fiber makes the cytoplasm more acidic, and eventually enzymes cease to function well. If fermentation continues longer than two or three minutes, cramping and fatigue set in. Cramping seems to be due to lack of the ATP needed to pump calcium ions back into the sarcoplasmic reticulum and to break the linkages between the actin and myosin filaments so that muscle fibers can relax.

Oxygen Deficit

When a muscle uses fermentation to supply its energy needs, it incurs an **oxygen deficit.** Oxygen deficit is obvious when a person continues to breathe heavily after exercising. The ability to run up an oxygen deficit is one of muscle tissue's greatest assets. Brain tissue cannot last nearly as long without oxygen as muscles can.

Repaying an oxygen deficit requires replenishing creatine phosphate supplies and disposing of lactic acid.

Lactic acid can be changed back to pyruvic acid and metabolized completely in mitochondria, or it can be sent to the liver to reconstruct glycogen. A marathon runner who has just crossed the finish line is not exhausted due to oxygen deficit. Instead, the runner has used up all the muscles', and probably the liver's glycogen supply. It takes about two days to replace glycogen stores on a high-carbohydrate diet.

People who train rely more heavily on cellular respiration than do people who do not train. In people who train, the number of muscle mitochondria increases, and so fermentation is not

needed to produce ATP. Their mitochondria can start consuming oxygen as soon as the ADP concentration starts rising during muscle contraction. Because mitochondria can break down fatty acid, instead of glucose, blood glucose is spared for the activity of the brain. (The brain, unlike other organs, can only utilize glucose to produce ATP.) Because less lactate is produced in people who train, the pH of the blood remains steady, and there is less of an oxygen deficit.

Energy sources for muscle contraction

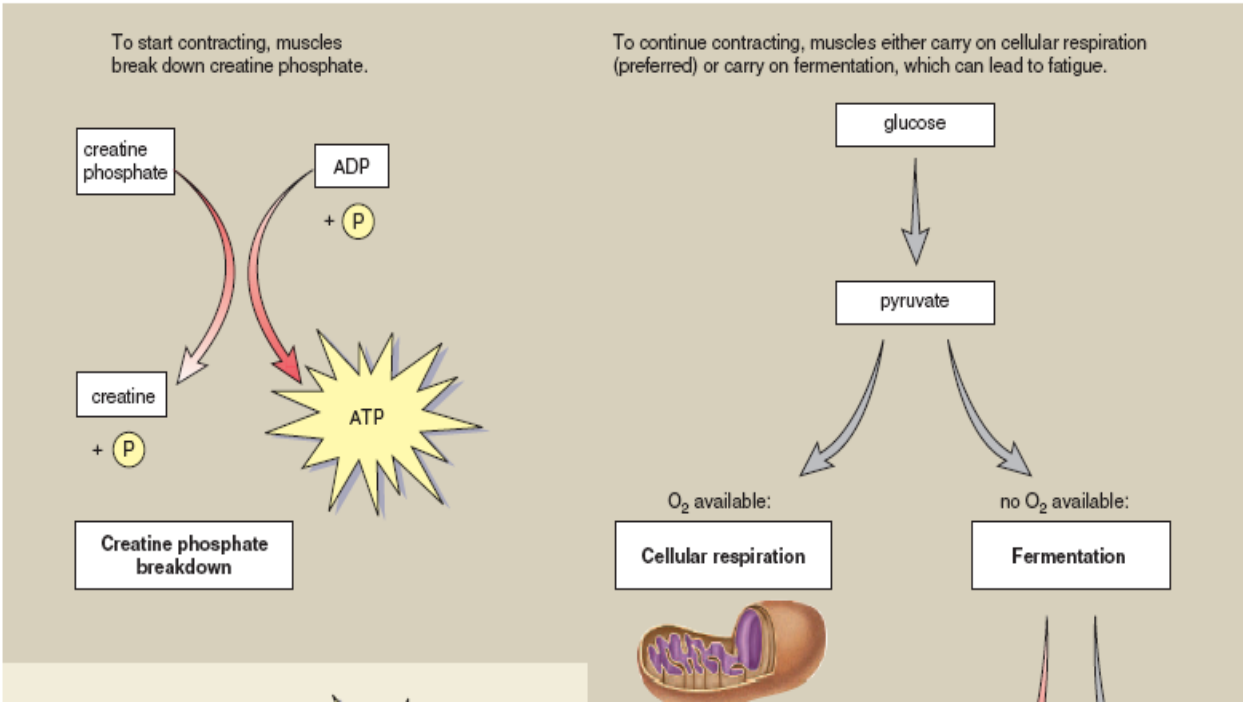

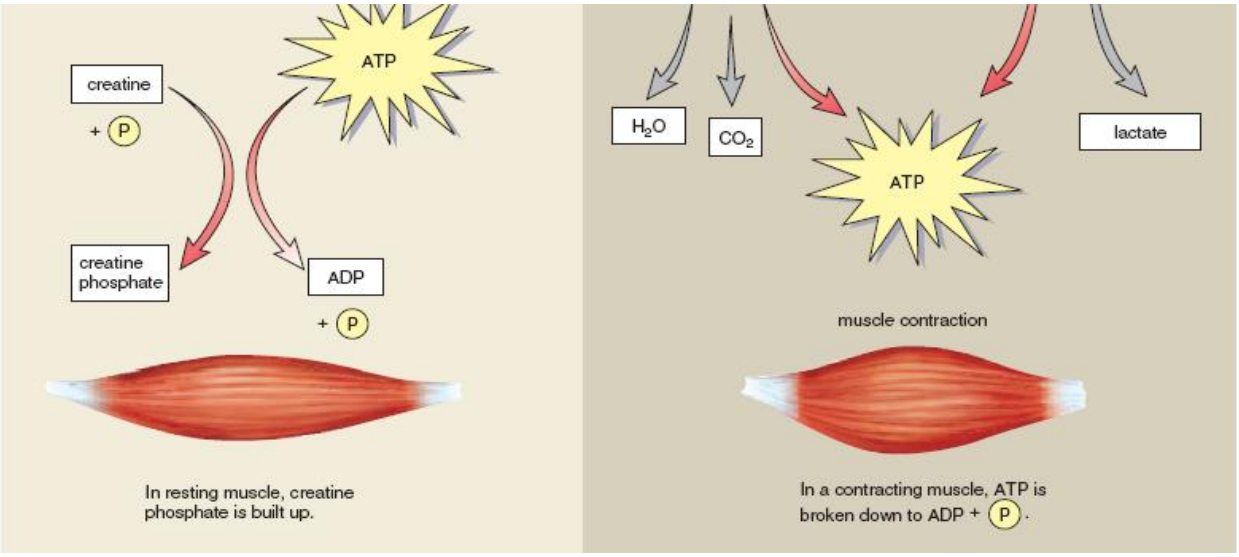

Muscle Responses

Muscles can be studied in the laboratory in an effort to understand how they respond when in the body.

In the Laboratory

When a muscle fiber is isolated, placed on a microscope slide, and provided with ATP plus the various electrolytes it requires, it contracts completely along its entire length. This observation has resulted in the **all-or-none law:** A muscle fiber contracts completely or not at all. In contrast, a whole muscle shows degrees of contraction. To study whole muscle contraction in the laboratory, an isolated muscle is stimulated electrically, and the mechanical force of contraction is recorded as a visual pattern called a *myogram*. When the strength of the stimulus is above a threshold level, the muscle contracts and then relaxes. This action—a single contraction that lasts only a fraction of a second is called a **muscle twitches.**

Figure below is a myogram of a muscle twitch, which is customarily divided into three stages: the latent period, or the period of time between stimulation and initiation of contraction; the contraction period, when the muscle shortens; and the relaxation period, when the muscle returns to its former length. It's interesting to use our knowledge of muscle fiber contraction to understand these events. From our study thus far, we know that a muscle fiber in an intact muscle contracts when calcium leaves storage sacs and relaxes when calcium returns to storage sacs. But unlike the contraction of a muscle fiber, a muscle has degrees of contraction, and a twitch can vary in height (strength) depending on the degree of stimulation. Why should that be? Obviously, a stronger stimulation causes more individual fibers to contract than before.

If a whole muscle is given a rapid series of stimuli, it can respond to the next stimulus without relaxing completely.

Summation is increased muscle contraction until maximal sustained contraction, called a **tetanic contraction,** is achieved.

The myogram no longer shows individual twitches; rather, the twitches are fused and blended completely into a straight line. Tetanus continues until the muscle *fatigues* due to depletion of energy reserves. Fatigue is apparent when a muscle relaxes even though stimulation continues.

In the Body

In the body, muscles are innervated to contract by nerves. As mentioned, each axon within a nerve stimulates a number of muscle fibers. A nerve fiber together with all of the muscle fibers it innervates is called a **motor unit.** A motor unit obeys the all-or-none law. Why?

Because all the muscle fibers in a motor unit are stimulated at once and they all either contract or do not contract

A variable of interest is the number of muscle fibers within a motor unit. For example, in the ocular muscles that move the eyes, the innervation ratio is one motor axon per 23 muscle fibers, while in the gastrocnemius muscle of the lower leg; the ratio is about one motor axon per 1,000 muscle fibers. No doubt, moving the eyes requires finer control than moving the legs.

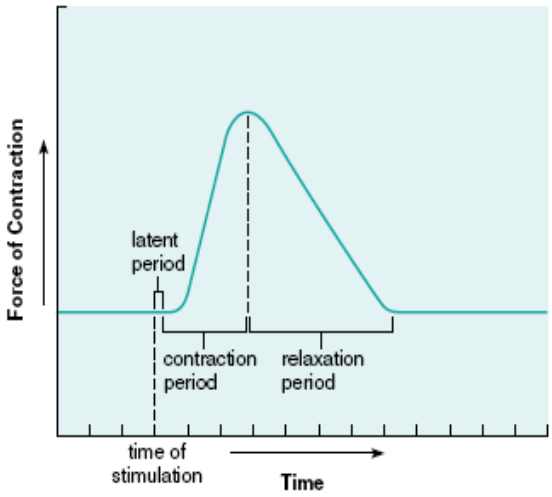

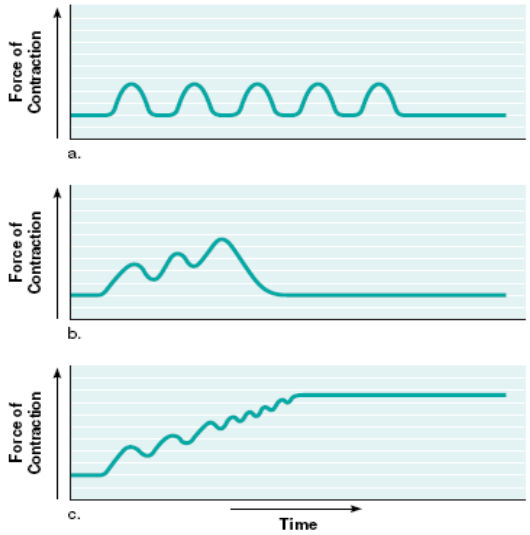

Tetanic contractions ordinarily occur in the body because, as the intensity of nervous stimulation increases, more and more motor units are activated.

This phenomenon, known as **recruitment** results in stronger and stronger muscle contractions

But while some muscle fibers are contracting, others are relaxing. Because of this, intact muscles rarely fatigue completely.

Even when muscles appear to be at rest, they exhibit **tone,** in which some of their fibers are always contracting.

Muscle tone is particularly important in maintaining posture.

If all the fibers within the muscles of the neck, trunk, and legs were to suddenly relax, the body would collapse.

Athletics and Muscle Contraction

Athletes who excel in a particular sport, and much of the general public as well, are interested in staying fit by exercising.

Exercise and Size of Muscles: Muscles that are not used or that are used for only very weak contractions decrease in size, or atrophy. **Atrophy** can occur when a limb is placed in a cast or when the nerve serving a muscle is damaged. If nerve stimulation is not restored, muscle fibers are gradually replaced by fat and fibrous tissue. Unfortunately, atrophy can cause muscle fibers to shorten progressively, leaving body parts contracted in contorted positions.

Forceful muscular activity over a prolonged period causes muscle to increase in size as the number of myofibrils within the muscle fibers increases. Increase in muscle size, called **hypertrophy,** occurs only if the muscle contracts to at least 75% of its maximum tension.

Some athletes take anabolic steroids, either testosterone or related chemicals, to promote muscle growth.

Slow-Twitch and Fast-Twitch Muscle Fibers We have seen that all muscle fibers metabolize both aerobically and anaerobically.

Some muscle fibers, however, utilize one method more than the other to provide myofibrils with ATP. Slowtwitch fibers tend to be aerobic, and fast-twitch fibers tend to be anaerobic

Slow-twitch fibers have a steadier tug and more endurance, despite having motor units with a smaller number of fibers.

These muscle fibers are most helpful in sports such as longdistance running, biking, jogging, and swimming. Because they produce most of their energy aerobically, they tire only when their fuel supply is gone. Slow-twitch fibers have many mitochondria and are dark in color because they contain myoglobin, the respiratory pigment found in muscles. They are also surrounded by dense capillary beds and draw more blood and oxygen than fast-twitch fibers. Slow-twitch fibers have a low maximum tension, which develops slowly, but these muscle fibers are highly resistant to fatigue. Because slow-twitch fibers have a substantial reserve of glycogen and fat, their abundant mitochondria can maintain a steady, prolonged production of ATP when oxygen is available.

Fast-twitch fibers tend to be anaerobic and seem to be designed for strength because their motor units contain many fibers. They provide explosions of energy and are most helpful in sports activities such as sprinting, weight lifting, swinging a golf club, or throwing a shot. Fast-twitch fibers are light in color because they have fewer mitochondria, little or no myoglobin, and fewer blood vessels than slow-twitch fibers do.

Fast-twitch fibers can develop maximum tension more rapidly than slow-twitch fibers can, and their maximum tension is greater. However, their dependence on anaerobic energy leavesthem vulnerable to an accumulation of lactic acid that causes them to fatigue quickly.

4.2.5. Skeletal Muscle Groups

There are more than 600 muscles in the body, which together account for about 40 percent of a person's weight.

Most skeletal muscles have names that describe some feature of the muscle. Often several criteria are combined into one name. Associating the muscle's characteristics with its name will help you learn and remember them. The following are some terms relating to muscle features that are used in naming muscles.

- ***Size***: vastus (huge); maximus (large); longus (long); minimus (small); brevis (short).
- ***Shape***: deltoid (triangular); rhomboid (like a rhombus with equal and parallel sides); latissimus (wide); teres (round); trapezius (like a trapezoid, a four-sided figure with two sides parallel).
- ***Direction*** of fibers: rectus (straight); transverse (across); oblique (diagonally); orbicularis (circular).
- ***Location***: pectoralis (chest); gluteus (buttock or rump); brachii (arm); supra- (above); infra- (below); sub- (under or beneath); lateralis (lateral).
- ***Number of origins***: biceps (two heads); triceps (three heads); quadriceps (four heads).
- ***Origin and insertion***: sternocleidomastoideus (origin on the sternum and clavicle, insertion on the mastoid process); brachioradialis (origin on the brachium or arm, insertion on the radius).

- ***Action:*** abductor (to abduct a structure); adductor (to adduct a structure); flexor (to flex a structure); extensor (to extend a structure); levator (to lift or elevate a structure); masseter (a chewer).

A. Muscles of the Head and Neck

Humans have well-developed muscles in the face that permit a large variety of facial expressions. Because the muscles are used to show surprise, disgust, anger, fear, and other emotions, they are an important means of nonverbal communication. Muscles of facial expression include frontalis, orbicularis oris, laris oculi, buccinator, and zygomaticus. These muscles of facial expressions are identified in the illustration below.

There are four pairs of muscles that are responsible for chewing movements or mastication. All of these muscles connect to the mandible and they are some of the strongest muscles in the body. Two of the muscles, temporalis and masseter are identified in the illustration above. There are numerous muscles associated with the throat, the hyoid bone and the vertebral column; only two of the more obvious and superficial neck muscles are identified in the illustration. They are sternocleidomastoid and trapezius.

Three general groups of muscles are found in the head and neck: those that move the head or neck, the muscles of facial expression, and the muscles for chewing.The muscles that turn or bend the head, such as the sternocleidomastoids (flexion) and the pair of splenius capitis muscles (extension), are anchored to the skull and to the clavicle and sternum anteriorly or the vertebrae posteriorly. The muscles for smiling or frowning or raising our eyebrows in disbelief are anchored to the bones of the head or to the undersurface of the skin of the face. The masseter is an important chewing muscle in that it raises the mandible (closes the jaw).

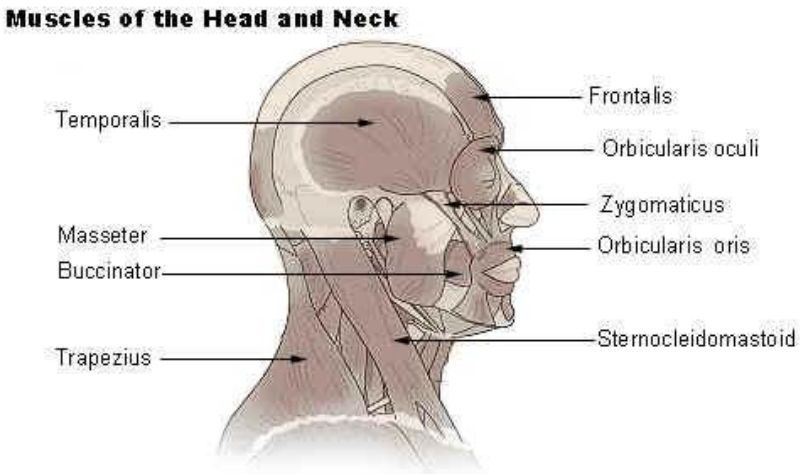

B. Muscles of the Trunk

The muscles of the trunk include those that move the vertebral column, the muscles that form the thoracic and abdominal walls, and those that cover the pelvic outlet.

The muscles of the trunk cannot be described with one or two general functions. Some form the wall of the trunk and bend the trunk, such as the rectus abdominis (f lexion) and the sacrospinalis group (extension). The trapezius (both together form the shape of a trapezoid) is a large muscle that can raise (shrug) the shoulder or pull it back, and can help extend the head.Other muscles found on the trunk help move the arm at the shoulder. The pectoralis major is a large muscle of the chest that pulls the arm across the chest (flexion and adduction). On the posterior side of the trunk, the latissimus dorsi pulls the arm downward and behind the back (extension and adduction). These muscles have their origins on the bones of the trunk, the sternum, or the vertebrae, which are strong, stable anchors. Another set of muscles forms the pelvic floor, where the muscles support the pelvic organs and assist with urination and defecation. Yet another category is the muscles that are concerned with breathing. Theseare the intercostal muscles between the ribs and the diaphragm that separates the thoracic and abdominalcavities.

The erector spinae group of muscles on each side of the vertebral column is a large muscle mass that extends from the sacrum to the skull. These muscles are primarily responsible for extending the vertebral column to maintain erect posture. The deep back muscles occupy the space between the spinous and transverse processes of adjacent vertebrae.

The muscles of the thoracic wall are involved primarily in the process of breathing. The intercostal muscles are located in spaces between the ribs. They contract during forced expiration. External intercostal muscles contract to elevate the ribs during the inspiration phase of breathing. The diaphragm is a dome-shaped muscle that forms a partition between the thorax and the abdomen. It has three openings in it for structures that have to pass from the thorax to the abdomen.

The abdomen, unlike the thorax and pelvis, has no bony reinforcements or protection. The wall consists entirely of four muscle pairs, arranged in layers, and the fascia that envelops them. The abdominal wall muscles are identified in the illustration below.

The pelvic outlet is formed by two muscular sheets and their associated fascia.

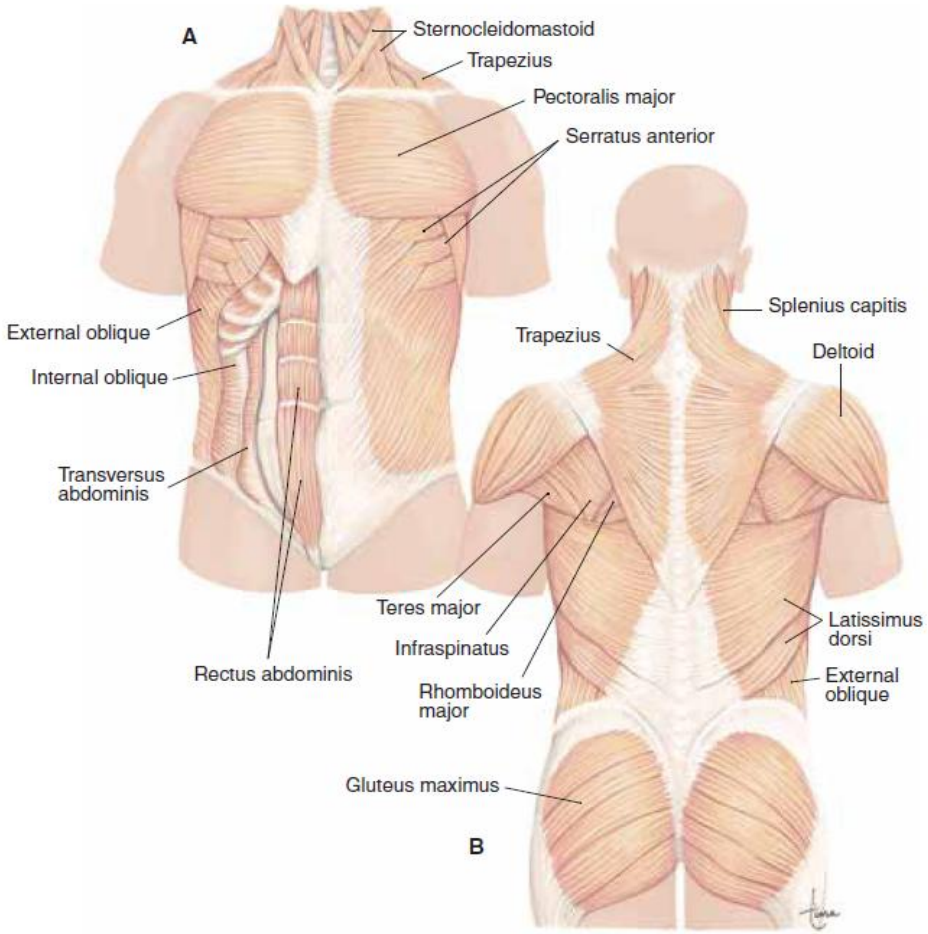

Figure: Muscles of the trunk. (**A**) Anterior view. (**B**) Posterior view.

C. Muscles of the shoulder and arm

The triangular deltoid muscle covers the point of the shoulder like a cap, and can pull the humerus to the side (abduction), forward (flexion), or backward (extension). The muscles that form the bulk of the forearm are the flexors and extensors of the hand and fingers. You can demonstrate this yourself by clasping the middle of your right forearm with your left hand, then moving your right hand at the wrist and closing and opening a fist; you can both feel and see the hand and fingermuscles at work.The muscles of the upper extremity include those that attach the scapula to the thorax and generally move the scapula, those that attach the humerus to the scapula and generally move the arm, and those that are located in the arm or forearm that move the forearm, wrist, and hand. The illustration below shows some of the muscles of the upper extremity.

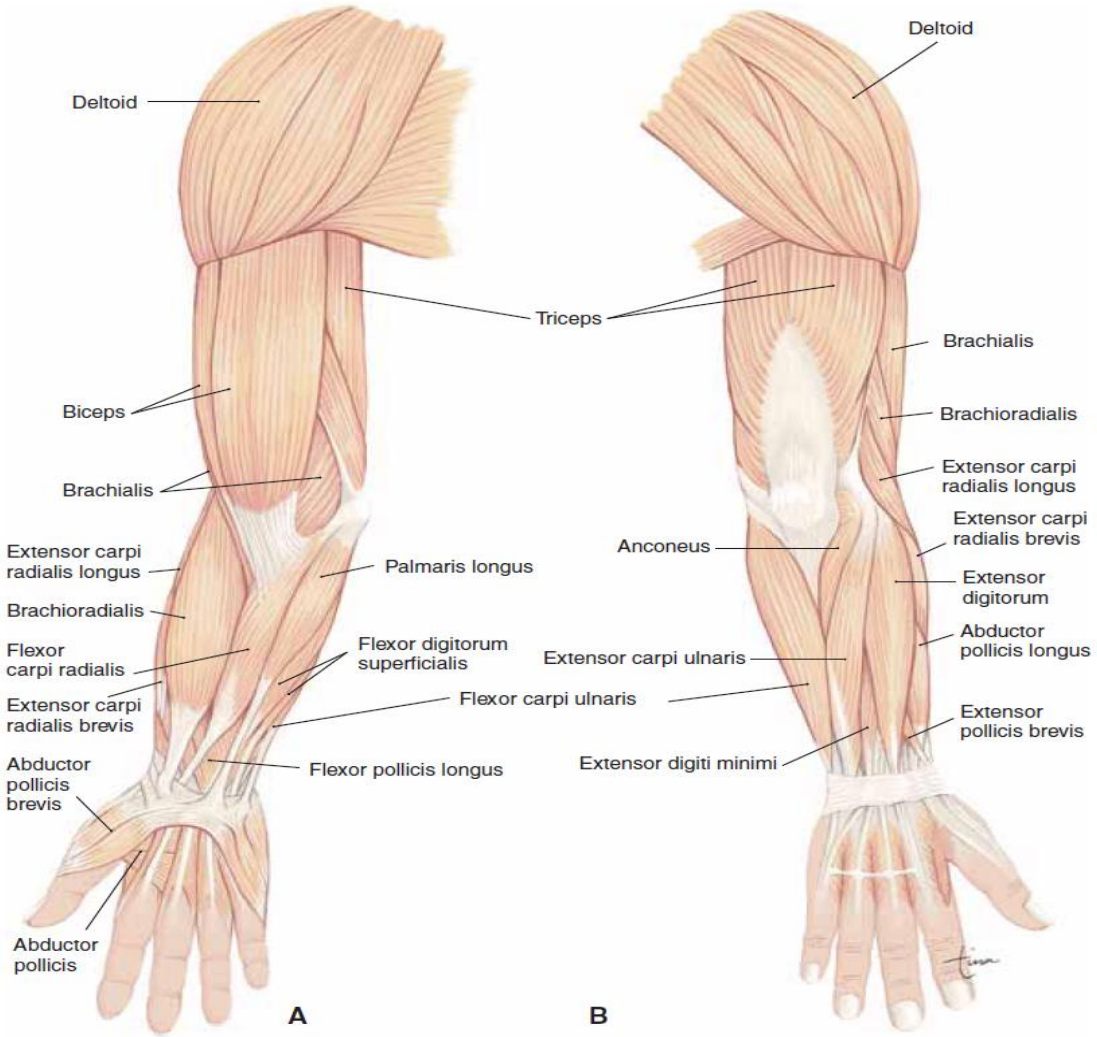

Figure: Muscles of the arm. (**A**) Anterior view. (**B**) Posterior view.

Muscles that move the shoulder and arm include the trapezius and serratus anterior. The pectoralis major, latissimus dorsi, deltoid, and rotator cuff muscles connect to the humerus and move the arm.The muscles that move the forearm are located along the humerus, which include the triceps brachii, biceps brachii, brachialis, and brachioradialis. The 20 or more muscles that cause most wrist, hand, and finger movements are located along the forearm.

D. Muscles of the hip and leg

The hip muscles that move the thigh are anchored to the pelvic bone and cross the hip joint to the femur. Among these are the gluteus maximus (extension), gluteus medius (abduction), and iliopsoas (flexion). The muscles that form the thigh include the quadriceps group anteriorly and the hamstring group posteriorly. For most people, the quadriceps is stronger than the hamstrings, which is why athletes more often have a "pulled hamstring" rather than a "pulled quadriceps." Movement of the knee joint depends on thigh muscles and lower leg muscles. Movement of the foot depends on lower leg muscles such as the gastrocnemius (dorsiflexion or flexion) and the tibialis anterior (plantar flexion or extension).

The largest muscle mass belongs to the posterior group, the gluteal muscles, which, as a group, abduct the thigh. The iliopsoas, an anterior muscle, flexes the thigh. The muscles in the medial compartment adduct the thigh.

E. Muscles of the female pelvic floor.

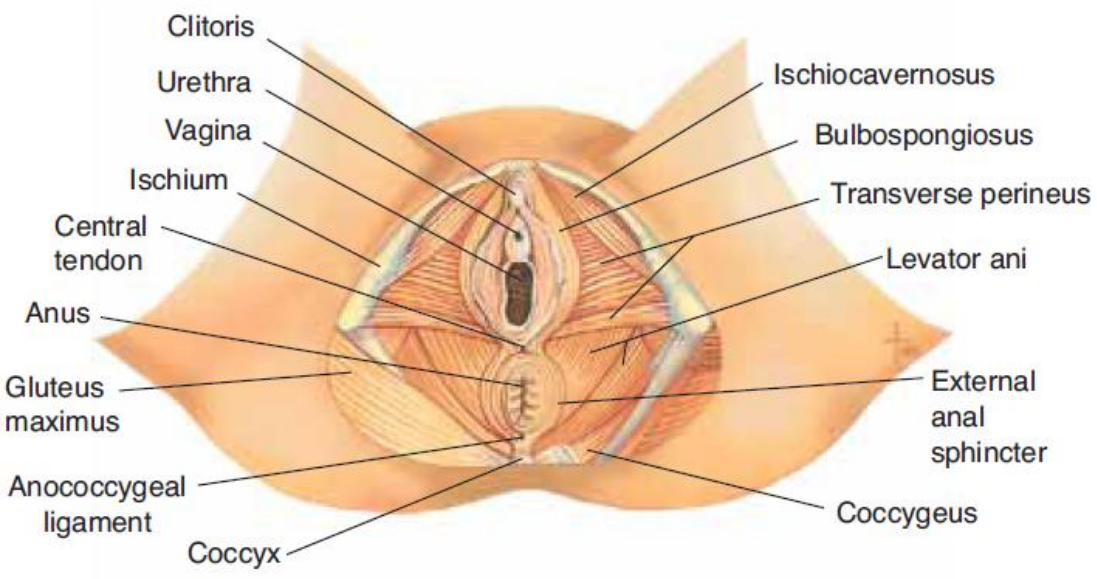

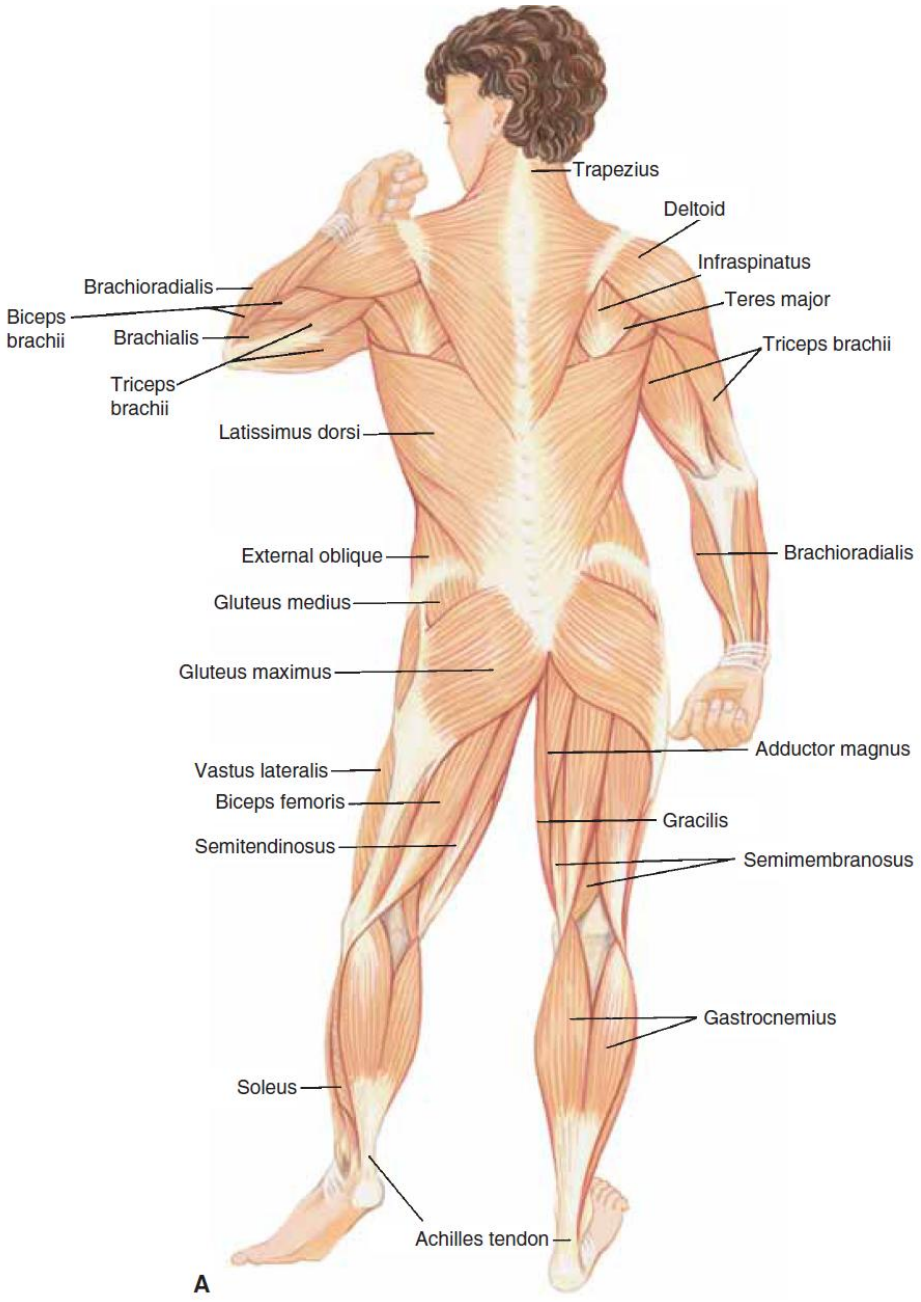

Figure: Major muscles of the body. (**A**) Posterior view.

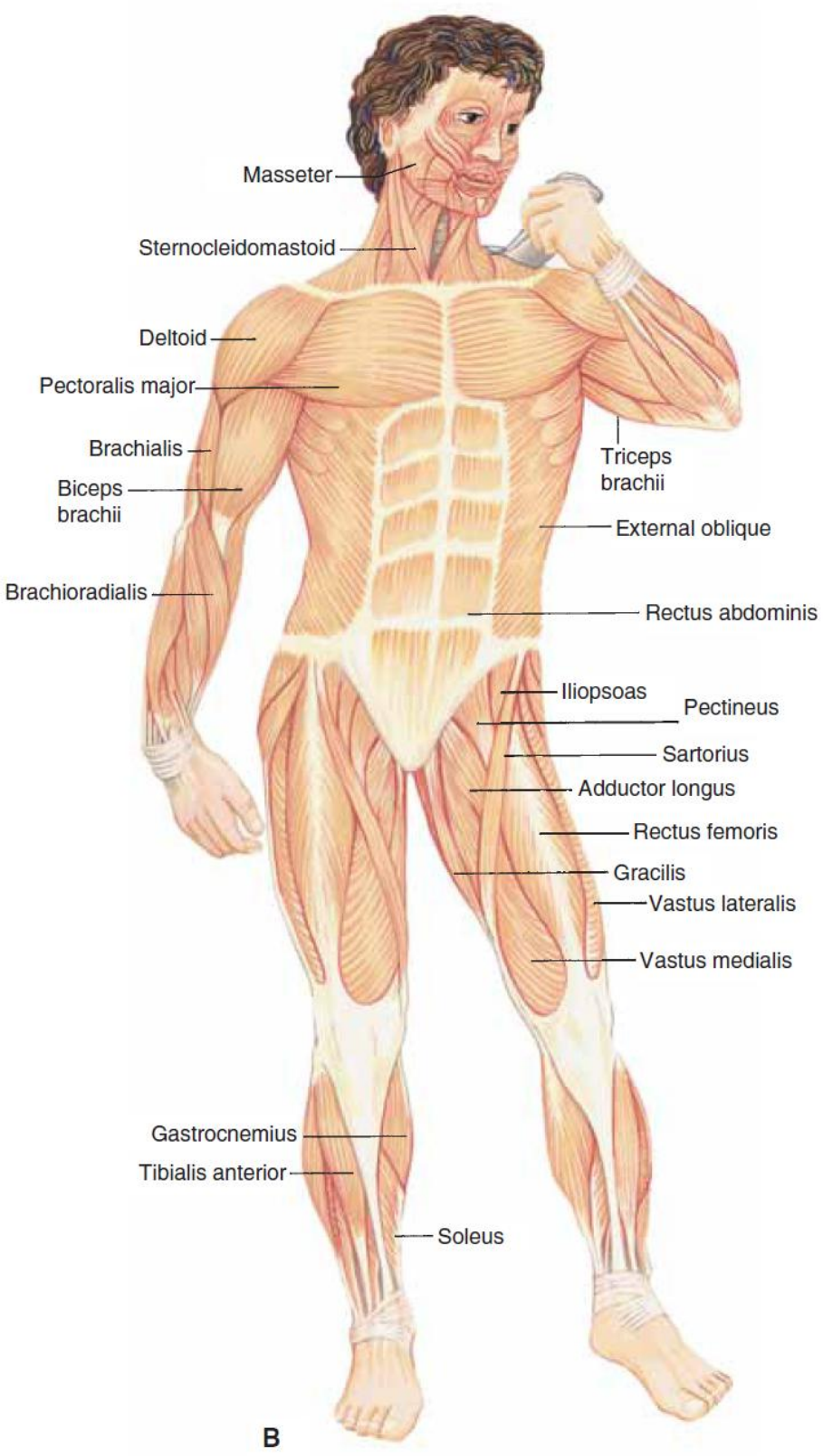

Figure: Major muscles of the body. (**A**) Anterior view.

MUSCLES OF THE HEAD AND NECK			
Muscle	**Function**	**Origin**	**Insertion**
Trapezius	Raises, lowers, and adducts shoulders	occipital bone and all thoracic vertebrae	spine of scapula and clavicle
External intercostals	Pull ribs up and out (inhalation)	superior rib	inferior rib
Internal intercostals	Pull ribs down and in (forced exhalation)	inferior rib	superior rib
Diaphragm	Flattens (down) to enlarge chest cavity for inhalation	last 6 costal cartilages and lumbar vertebrae	central tendon
Rectus abdominis	Flexes vertebral column, compressesabdomen	pubic bones	5th–7th costal cartilages and xiphoid process
External oblique	Rotates and flexes vertebral column, compresses abdomen	lower 8 ribs	iliac crest and linea alba
Sacrospinalis group (deep muscles)	Extends vertebral column	ilium, lumbar, and some thoracic vertebrae	ribs, cervical, and thoracic vertebrae
MUSCLES OF THE TRUNK			
Trapezius	Raises, lowers, and adducts Shoulders	• occipital bone and all thoracic vertebrae	• spine of scapula and clavicle
External intercostals	Pull ribs up and out (inhalation)	• superior rib	• inferior rib
Internal intercostals	Pull ribs down and in (forced exhalation)	• inferior rib	• superior rib
Diaphragm	Flattens (down) to enlarge chest cavity for inhalation	• last 6 costal cartilages and lumbar vertebrae	• central tendon
Rectus abdominis	Flexes vertebral column, compresses abdomen	• pubic bones	• 5th–7th costal cartilages and xiphoid process
External oblique	Rotates and flexes vertebral column, compresses abdomen	• lower 8 ribs	• iliac crest and linea alba
Sacrospinalis group (deep muscles)	Extends vertebral column	• ilium, lumbar, and some thoracic vertebrae	• ribs, cervical, and thoracic vertebrae

MUSCLES OF THE SHOULDER AND ARM			
Deltoid	Abducts the humerus	scapula and clavicle	Humerus
Pectoralis major	Flexes and adducts the humerus	clavicle, sternum, 2nd–6th costal cartilages	Humerus
Latissimus dorsi	Extends and adducts the humerus	last 6 thoracic vertebrae, all lumbar vertebrae, sacrum, iliac crest	Humerus
Teres major	Extends and adducts the humerus	Scapula	Humerus
Triceps brachii	Extends the forearm	humerus and scapula	Ulna
Biceps brachii	Flexes the forearm	Scapula	Radius
Brachioradialis	Flexes the forearm	Humerus	Radius
MUSCLES OF THE HIP AND LEG			
Iliopsoas	Flexes femur	ilium, lumbar vertebrae	Femur
Gluteus maximus	Extends femur	iliac crest, sacrum, coccyx	Femur
Gluteus medius	Abducts femur	Ilium	Femur
Quadriceps femoris group: Rectus femoris Vastus lateralis Vastu smedialis Vastus intermedius	Flexes femur and extends lower leg	ilium and femur	Tibia
Hamstring group: Biceps femoris Semimembranosus Se-mitendinosus	Extends femur and flexes lower leg	Ischium	tibia and fibula
Adductor group	Adducts femur	ischium and pubis	Femur
Sartorius	Flexes femur and lower leg	Ilium	Tibia

Gastrocnemius	Plantar flexes foot	Femur	calcaneus (Achilles tendon)
Soleus	Plantar flexes foot	tibia and fibula	calcaneus (Achilles tendon)
Tibialis anterior	Dorsiflexes foot	Tibia	Metatarsals
MUSCLES OF THE PELVIC FLOOR			
Levator ani	Supports pelvic organs, especially during defecation, urination, coughing, and forced exhalation; constricts anus, urethra, and vagina	pubis and ischium	coccyx, anal canal,urethra
Coccygeus	Supports pelvic organs, especially during defecation, urination, coughing, and forced exhalation	Ischium	coccyx and sacrum
Ischiocavernosus	Erection of clitoris in female, penis in male	ischium and pubis	clitoris or penis
Bulbospongiosus	Assists urination; erection in female;erection and ejaculation in male	central tendon of perineum	fasciae, pubic arch,clitoris, or penis
Transverse perineus (superficial and deep)	Assists urination in female; urination and ejaculation in male	Ischium	central tendon of perineum
External anal sphincter	Closes anus	Anococcygeal ligament	central tendon of perineum

4.3. MOVEMENTS AND POSITIONS OF THE BODY

Muscle actions are always described as departures from the standard position of the body, the anatomical position. Certain of these actions are general, and can be applied to several regions of the body, while others are quite specific to a single region or even a single joint.

- ✓ **Flexion/Extension:** This pair of actions occurs about a transverse axis through a joint. The movement at a joint which decreases the angle between two adjacent body segments is known as flexion. The opposite action is extension, where the angle between body segments is increased.
- ✓ **Abduction/Adduction:** These actions are possible about an axis arranged in an antero-posterior direction through a joint. A movement of a body part away from the midline, either of the body as a whole or that of the hand or foot, is termed abduction (L., to carry away). A movement of the body part back toward the midline (i.e., to the anatomical position) is known as adduction.
- ✓ **Lateral /Medial Rotation:** Rotation occurs about a longitudinal (vertical) axis passing through a joint and through the length of the bone distal to it. A reference point must be identified on the lateral aspect of the distal bone. (The flexed forearm can indicate this reference point.) Lateral rotation is the opposite action. The reference point is moved posteriorly or laterally, away from the body midline. Medial rotation involves torsion of the distal bone so that the reference point is moved anteriorly or medially toward the body midline.
- ✓ **Circumduction:** A combination of the actions of flexion, abduction, extension and adduction, in that order, is known as circumduction. This is a composite action, involving two axes of rotation: the transverse axis and the antero-posterior axis, and both actions allowed at each axis.

A. Actions of the Scapula

Several of the special muscle actions occur in the movement of the scapula. The scapula is rather firmly connected to the clavicle via the Acromioclavicular joint, hence these two bones move together as a single unit. The functional joint which allows them to move is the sternoclavicular joint, located at the superior aspect of the sternum. All the axes of rotation in-

volving the scapula must therefore pass through the sternoclavicular joint, and movements of the scapula must be understood to occur at that joint.

✓ ***Elevation/Depression***

On an anteroposterior axis through the sternoclavicular joint, the scapula, with its attached musculature, is able to be raised to a more superior level, or elevated ("shrugging the shoulders"). The opposite action, depression, involves the pulling down of the scapula to a more inferior position.

✓ ***Protraction/Retraction***

The vertical axis through the sternoclavicular joint allows the scapula to be moved forward, an action termed protraction (as in "hunching the shoulders"). The action opposite to this would be one of retraction, or movement of the scapula backwards (as in "squaring the shoulders").

✓ ***Rotation***

The scapula is also capable of being rotated upward and downward around a reference point at the tip of the shoulder. This action occurs around an oblique angle passing through the sternoclavicular joint and the scapula bone just below the shoulder joint. The scapula can be rotated upward around this axis, allowing a full upward swing (abduction) of the upper limb. Or it can be rotated downward, pushing the inferior angle of the scapula close to the midline of the body.

B. Special Actions of the Foot

Two specialized actions are allowed for the foot: one pair at the ankle joint and the other between bones of the foot itself. The actions of the ankle are plantar flexion and dorsiflexion; those of the foot are version and inversion.

✓ ***Dorsiflexion/Plantar Flexion***

A transverse axis through the ankle joint allows a pair of actions similar to flexion and extension at the wrist joint. The analogous action to wrist flexion is one that would tip the sole of the foot downward, increasing the angle between foot and leg.

The usual term for the increase in such an angle would be extension, but in order to emphasize the relation between foot and hand, this action is instead termed plantar flexion.

The action similar to extension at the wrist would be a tipping of the upper surface (dorsum) of the foot toward the anterior surface of the leg. However, this would decrease the angle between the body segments, and action usually termed flexion. Since the term, plantar flexion, has been used for the opposite action, this is now referred to as dorsiflexion.

✓ ***Aversion/Inversion***

These special actions of the foot occur as a result of movement between two major joint complexes of the foot. The resulting angle of rotation is oblique, from the medial side of the heel to the lateral side of the mid-foot. ***Inversion*** is the action of turning the sole of the foot inward, towards the opposite foot. ***Aversion*** is the movement of turning the sole of the foot outward, away from the midline.

C. Movements of the Hand

In the hand and foot, a specific application is utilized for the general terms abduction and adduction. In addition, movement of certain of the metacarpals (or metatarsals) occurs at their joint with carpal bones of the wrist (or tarsals of the foot). This action is termed opposition.

✓ ***Abduction/Adduction***

The actions of abduction and adduction were previously described with regard to movements relating to the body as a whole. However, they may also be used to describe actions of the fingers and toes away from (abduction) or toward (adduction) a reference point.

✓ ***Opposition***

Opposition is a special action of the hand, whereby the thumb and little finger are brought around to touch the fingertips. This action occurs at the joints between the carpal bones and the metacarpals of the thumb and little finger.

✓ ***Pronation/Supination***

Another special action occurs in the forearm, where the radius and ulna are arranged in such a way as to allow the crossing of the distal end of the radius over the ulna. An oblique angle of rotation occurs here, passing through the head of the radius (proximally) and the styloid process of the ulna (distally). The specialized movements occurring here are pronation and supination.

Pronation is the movement of crossing the radius over the ulna. This movement results in the dorsal surface of the hand turning forward, or prone. Supination is the opposite action, wherein the radius is uncrossed and the palmar surface of the hand is returned to the anatomical position, or supine (forward).

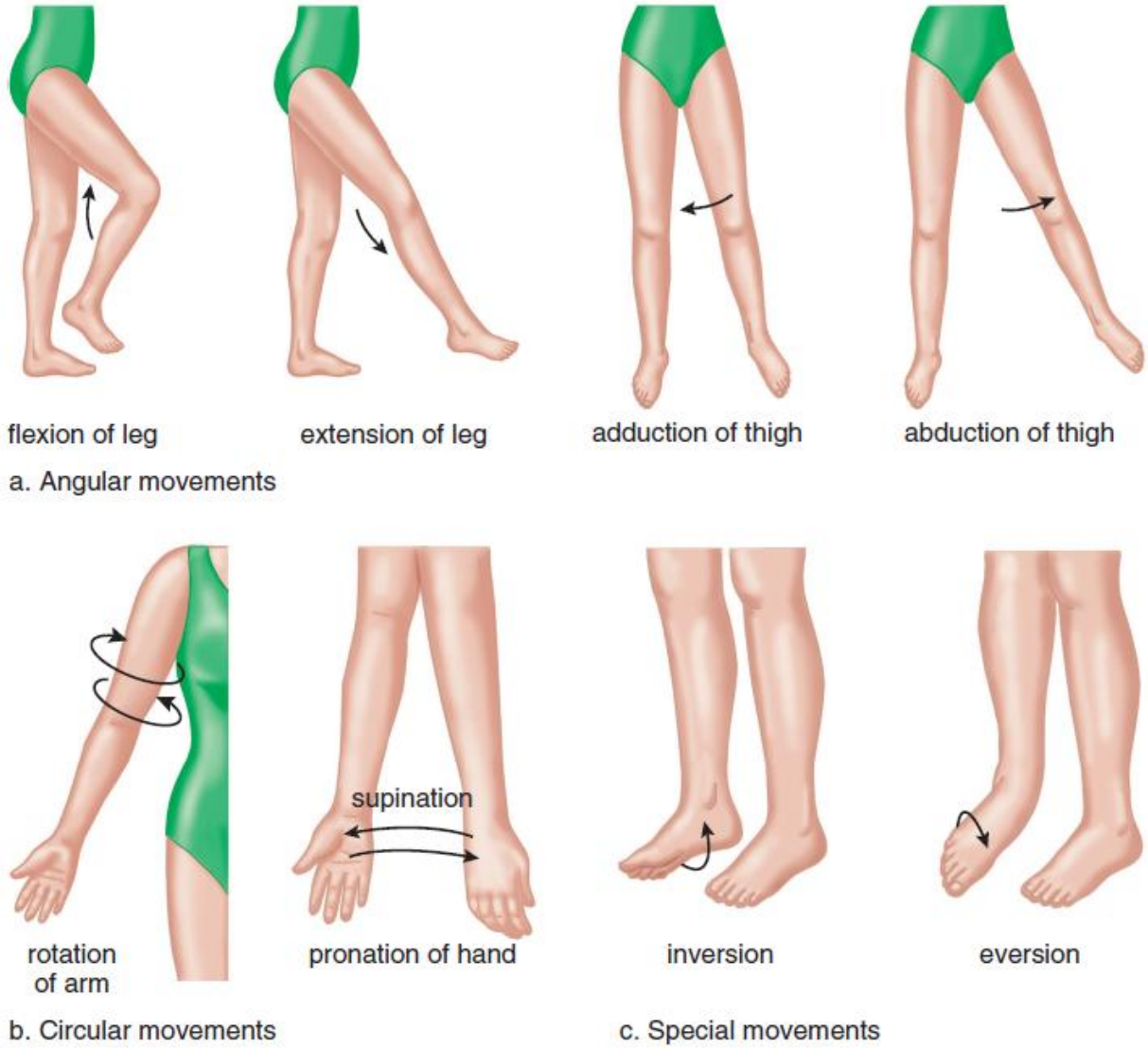

AGING AND THE MUSCULAR SYSTEM

With age, muscle cells die and are replaced by fibrous connective tissue or by fat. Regular exercise, however, delays atrophy of muscles. Although muscles become slower to contract and their maximal strength decreases, exercise can maintain muscle functioning at a level that meets whatever a person needs for daily activities. The lifting of small weights is recommended as exercise for elderly people, women as well as men. Such exercise also benefits the cardiovascular, respiratory, and skeletal systems.The loss of muscle fibers also contributes to a loss of proprioception, because the brain is getting less information about where and how the body is positioned. The loss of muscle sense contributes to unsteadiness in elderly people and to an impaired sense of balance, which in turn may lead to a fall. Simple awareness of this may help an elderly person prevent such accidents.

- **Applications to the nursing care**

1. TETANUS AND BOTULISM

Some bacteria cause disease by producing toxins. A **neurotoxin** is a chemical that in some way disrupts the normal functioning of the nervous system. Because skeletal muscle contraction depends on nerve impulses, the serious consequences for the individual may be seen in the muscular system.

Tetanus is characterized by the inability of muscles to relax. The toxin produced by the tetanus bacteria (*Clostridium tetani*) affects the nervous system in such a way that muscle fibers receive too many impulses, and muscles go into spasms. Lockjaw, the common name for tetanus, indicates one of the first symptoms, which is difficulty opening the mouth because of spasms of the masseter muscles. Treatment requires the antitoxin (an antibody to the toxin) to neutralize the toxin. In untreated tetanus the cause of death is spasm of the respiratory muscles.

Botulism is usually a type of food poisoning, but it is not characterized by typical food poisoning symptoms such as diarrhea or vomiting. The neurotoxin produced by the botulism bacteria (*Clostridium botulinum*) prevents the release of acetylcholine at neuromuscular junctions. Without acetylcholine, muscle fibers cannot contract, and muscles become paralyzed.

Early symptoms of botulism include blurred or double vision and difficulty speaking or swallowing. Weakness and paralysis spread to other muscle groups, eventually affecting all voluntary muscles. Without rapid treatment with the antitoxin (the specific antibody to this toxin), botulism is fatal because of paralysis of the respiratory muscles.

2. MUSCULAR DYSTROPHY

Muscular dystrophy is really a group of genetic diseases in which muscle tissue is replaced by fibrous connective tissue or by fat. Neither of these tissues is capable of contraction, and the result is progressive loss of muscle function. The most common form is Duchenne's muscular dystrophy, in which the loss of muscle function affects not only skeletal muscle but also cardiac muscle. Death usually occurs before the age of 20 due to heart failure, and at present there is no cure.

Duchenne's muscular dystrophy is a **sexlinked** (or X-linked) **trait**, which means that the gene for it is on the X chromosome and is recessive. The female sex chromosomes are XX. If one X chromosome has a gene for muscular dystrophy, and the other X chromosome has a dominant gene for normal muscle function, the woman will not have muscular dystrophy but will be a carrier who may pass the muscular dystrophy gene to her children. The male sex chromosomes are XY, and the Y has no gene at all for muscle function, that is, no gene to prevent the expression of the gene on the X chromosome. If the X chromosome has a gene for muscular dystrophy, the male will have the disease.

This is why Duchenne's muscular dystrophy is more common in males; the presence of only one gene means the disease will be present. The muscular dystrophy gene on the X chromosome has been located, and the protein the gene codes for has been named *dystrophin*. Dystrophin is necessary for the stability of the sarcolemma and the proper movement of ions. Treatments for muscular dystrophy that are being investigated include the injection of normal muscle cells or stem cells into affected muscles, and the insertion (using viruses) of normal genes for dystrophin into affected muscle cells.

3. *MYASTHENIA GRAVIS*

Myasthenia gravis is an **autoimmune** disorder characterized by extreme muscle fatigue even after minimal exertion. Women are affected more often than are men, and symptoms usually begin in middle age. Weakness may first be noticed in the facial or swallowing muscles and may progress to other muscles. Without treatment, the respiratory muscles will eventually be affected, and respiratory failure is the cause of death.

In myasthenia gravis, the autoantibodies (selfantibodies) destroy the **acetylcholine receptors** on the sarcolemma. These receptors are the sites to which acetylcholine bonds and stimulates the entry of Na_ ions. Without these receptors, the acetylcholine released by the axon terminal cannot cause depolarization of a muscle fiber.

Treatment of myasthenia gravis may involve anticholinesterase medications. Recall that cholinesterase is present in the sarcolemma to inactivate acetylcholine and prevent continuous, unwanted impulses. If this action of cholinesterase is inhibited, acetylcholine remains on the sarcolemma for a longer time and may bond to any remaining receptors to stimulate depolarization and contraction.