CHAPTER 2: BODY TISSUES AND MEMBRANES

At the end of this chapter, student will be able to:

a) Describe the general characteristics of each of the four major categories of tissues.
b) Describe the functions of the types of epithelial tissues with respect to the organs in which they are found.
c) Describe the functions of the connective tissues, and relate them to the functioning of the body or a specific organ system.
d) Explain the differences, in terms of location and function, among skeletal muscle, smooth muscle, and cardiac muscle.
e) Name the three parts of a neuron and state the function of each.
f) Explain the function of serous fluid.
g) State the locations of mucous membranes and the functions of mucus.

1. TISSUES

Knowledge of tissue structure and function is important in understanding the structure and function of organs, organ system and the complete organism. A *tissue* is a group of cells with similar structure and function. Specialized cells and the extracellular matrix surrounding them form all the tissue types found at the tissue level of organization. *Histology* is the microscopic study of tissues.

1.1. Embryonic tissue

Approximately 13 or 14 days after fertilization, the cells that give rise to the new individual, called embryonic stem cells form a slightly elongated disk consisting of two layers called the **ectoderm** and the **endoderm**. Cells of ectoderm then migrate between the two layers to form a third layer called **mesoderm**. The ectoderm, mesoderm and endoderm are called germ layers because the beginning of all adult structures can be traced back to one of them and they give rise to all tissues of the body.

- **The endoderm**, the inner layer, forms the lining of the digestive tract and its derivatives.

- **The mesoderm**, the middle layer, forms tissues such as muscle, bone, and blood vessels.
- **The ectoderm**, the outer layer, forms the skin and a portion of the ectoderm called ***neuroectoderm*** becomes the nervous system.

Groups of cells that break away from the neuroectoderm during development, called **neural crest cells**, give rise to parts of the peripheral nerves, skin pigment, the medulla of the adrenal gland and many tissues of the face.

1.2. Classification of tissues

Tissues are classified based on the structure of the cells, the composition of the noncellular substances surrounding cells, called the **extracellular matrix** and the function of the cells.

The four primary tissue types, which include all tissues, and from which all organs of the body are formed, are:

1. Epithelial tissue
2. Connective tissue
3. Muscle tissue
4. Nervous tissue.

1.2.1 Epithelial tissue

Epithelial tissue is a protective covering of surfaces, both outside and inside the body. Six characteristics common to the most types of epithelium are:

1. Epithelium consists almost entirely of cells, with very little extracellular matrix between them.
2. Covers surfaces of the body and forms glands. The body surface means outside surface of the body; the lining of the digestive and respiratory tracts, the heart and blood vessels, and the lining of many cavities.
3. Have one free or apical surface not attached to other cells; a lateral surface attached to other epithelial cells; and a basal surface. The free surface often lines the lumen of ducts, vessels, or cavities. The basal surface of most epithelial tissues is attached to a **basement membrane**, which is specialized type of extracellular material secreted by the epithelial

cells and by connective tissue cells. It is like the adhesive on Scotch tape. It helps attach the epithelial cells to the underlying tissues and it plays an important role in supporting and guiding cell migration during tissue repair.

4. Specialized cell contacts binding adjacent epithelial cells together.
5. Blood vessels in underlying connective tissue do not penetrate the basement membrane to reach the epithelium; thus, all gases and nutrients carried in the blood must reach the epithelium by diffusing from blood vessels with many layers of cells, the most metabolically active cells are close to the basement membrane,
6. Epithelial cells retain the ability to undergo mitosis and therefore are able to replace damaged cells with new epithelial cells. Undifferentiated cells (stem cells) continuously divide and produce new cells. In some types of epithelial tissues, such as in the skin and in the digestive tract, cells that are lost or die are continuously replaced by the new cells.

A. Functions of Epithelial Tissue

Major functions of epithelial tissue include:

1. Protecting underlying structures (outer layer of the skin & the epithelium of oral cavity which protect the underlying structures from abrasion)
2. Acting as barriers(the skin acts as a barrier to water and reduce water loss from the body; barrier to many toxic molecules and microorganisms)
3. Permitting the passage of substances (Oxygen and carbon dioxide are exchanged between the air and blood by diffusion through the epithelium in the lungs; epithelium acts as a filter in the kidney, allowing many substance to pass from the blood into the urine but retaining other substances, such as blood cell and proteins, in the blood.)
4. Secreting substances (Mucous glands, sweat glands, and the enzyme-secreting portion of the pancreas secrete their products onto the epithelial surfaces or into ducts that carry them to other areas of the body).
5. Absorbing substances (the plasma membrane of certain epithelial tissue contains carrier **proteins. (**Facilitated diffusion**).**

B. Classification of epithelial tissues

Epithelium is classified primarily according to the number of cells layers and the shape of the superficial cells.

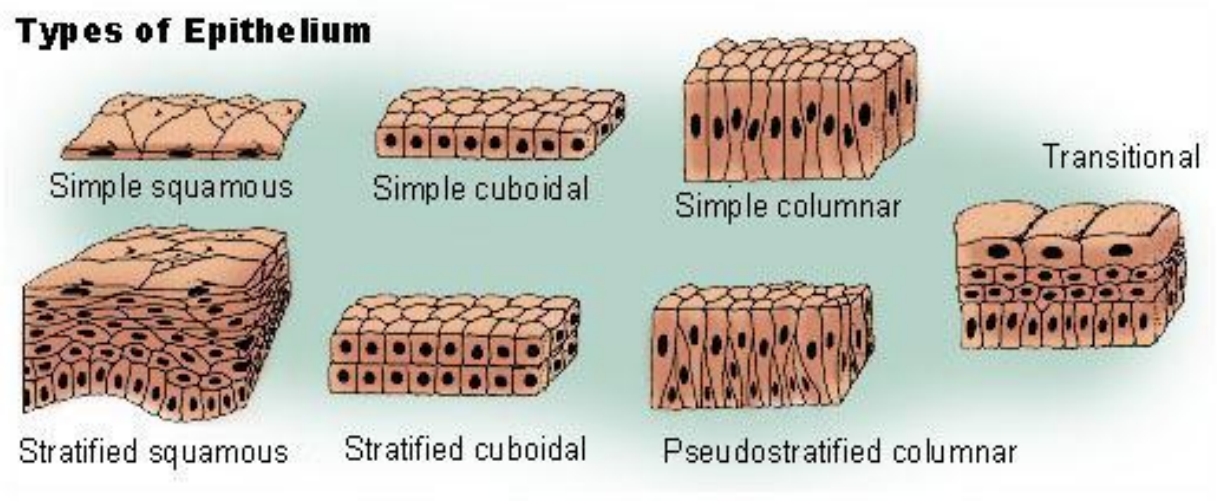

There are three major types of epithelium based on the number of cell layers in each type:

1. **Simple epithelium** consists of a single layer of cells, with each cell extending from the basement membrane to the free surface.
2. **Stratified epithelium** consists of more than one layer of cells, but only the basal layer of cells attaches the deepest layer to the basement membrane.
3. **Pseudo stratified columnar epithelium** is especial type of simple epithelium. (Pseudo= false, so this type of epithelium appears to be stratified but is not.).

There are three types of epithelium based on the shape of the epithelial cells:

1. **Squamous**: cells are flat or scale like.
2. **Cuboidal** : cells are cube –shaped ; they are about as wide as they are tall
3. **Columnar**: tall and thin, similar to a column) cells are taller than they are wide.

In the most cases, an epithelium is given two names, such as simple squamous, stratified squamous, simple columnar, or pseudo stratified columnar. The first name indicates the number of layers, and the second indicate the shape of the cells.

Cell surface

The free surfaces of epithelial tissues can be smooth, contains microvilli, be ciliated, or be folded.

- ✓ **Smooth surfaces** reduce friction. The lining of blood vessels is a simple squamous epithelium that reduces friction as blood flow through the vessels.
- ✓ **Microvilli** are nonmotile and contain microfilaments. They greatly increase surface area and are found in cells that absorb or secrete, such as serous membrane or the lining of the small intestine.
- ✓ **Stereocilia** are elongated microvilli. They are found in sensory structures, such as the inner ear, and they play a role in sound detection. They are found in some places where absorption is important, such as in the epithelium of the epididymis.
- ✓ **Cilia** contain microtubules and they move materials across the surface of the cell.

Transitional epithelium has a rather unusual plasma membrane specialization: more rigid sections of membrane are separated by very flexible regions in which the plasma membrane is folded. Transitional epithelium is specialized to extend. It is found in the urinary bladder, ureters, kidney, pelvis, calyces of the kidney, and superior part of the urethra.

Functions, types and location of epithelium tissues

Function	Simple squamous epithelium	Simple cuboidal epithelium	Simple columnar Epithelium	Stratified squamous epithelium	Stratified cuboidal epithelium	Stratified columnar epithelium	Pseudo stratified columnar epithelium	Transitional Epithelium
Diffusion	Blood and lymph capillaries, alveoli of lungs, thin segments of loops of Henle.							
Filtration	Bowman's capsules of kidneys							
Secretion or absorption	Mesothelium (serous fluid)	Choroid plexus (produce cerebrospinal fluid), part of kidney tubules, many glands and their ducts.	Stomach, small intestine, large intestine, uterus, many glands.					
Protection (against friction and	Endothelium (e.g. epithelium of blood vessels);			Skin (epidermis), corneas, mouth and				

absorption)	Mesothelium (e.g epithelium of body cavities)			throat, epiglottis, larynx, esophagus, anus, vagina				
Movement of mucus (ciliated)		Terminal bronchioles of lungs	Bronchioles of lungs, auditory tubes, uterine tubes, uterus				Larynx, nasal cavity, paranasal sinuses, nasopharynx, auditory tubes, trachea, bronchi of lungs.	
Capable of great stretching								Urinary bladder, ureter, superior part of urethra.
Miscellaneous	Inner part of the eardrums, smallest ducts of glands	Surface of ovaries, inside lining of eyes (pigmented epithelium of retina, ducts of glands	Bile duct, gallbladder, ependyma (lining of brain ventricles and central canal of spinal cord), ducts of glands.	Lower part of urethra, sebaceous gland ducts.	Sweat gland ducts	Part of male urethra, epididymides , ductus deferens, mammary gland ducts.	Part of male urethra, salivary gland ducts.	

1.2.2 Connective tissue

The major structural characteristic that distinguishes connectives tissue from other three tissue types is that it consists of cells separated from each other by abundant extracellular matrix.

Functions of connective tissue

1. ***Enclosing and separating***: capsule around organs such as liver, kidney. Also connective tissue also forms the layers that separate tissues and organs. (For example connective tissues separate muscles, arteries, veins, and nerves from one another.)
2. ***Connecting tissues to one another*** (e.g tendons are strong cables, or bands, of connective tissue that attaches muscles to bone, and ligaments are connective tissues bands that holds bones together.
3. ***Supporting and moving****:* Bone of the skeletal system provides rigid support for the body; semi-rigid cartilage supports structures such as the nose, ears, and the surfaces of joints. Joints between bones allow one part of the body to move relative to other parts.
4. ***Storing:*** Adipose tissue (fat) stores high-energy molecules, and bones store minerals such as calcium and phosphate.
5. ***Cushioning and insulating***: Adipose tissue cushions and protects the tissue it surrounds and provides an insulating layer beneath the skin that helps conserve heat.
6. ***Transporting*** :Blood transports substances throughout the body, such as gases, nutrients, enzymes, hormones and cells of the immune system)
7. ***Protecting****:* Cells of the immune system and blood provide protection against toxins and tissue injury, as well as from micro-organisms. Bones protect underlying structures from injury.

1.2.2.1 Cells of connective tissues

The names of the cells end with suffixes that identify the cell functions as blasts, cytes, or clasts.

- ✓ **Blasts** create the matrix, **cytes** maintain it, and **clasts** break it down for remodeling. For example, **Fibroblasts** are cells that form fibrous connective tissue and **fibrocytes**

maintain it. **Chondroblasts** form cartilage (chondro- refers to cartilage) and **chondrocytes** maintain it. **Osteoblasts** form bone (osteo-means bone), **osteocytes** maintain it, and **osteoclasts** break it down.

- ✓ **Adipose** or **fat cells** also called **adipocytes** contain large amounts of lipid. Adipocytes are predominant in adipose tissue.
- ✓ **Mast cells** are commonly found beneath membrane s in loose connective tissue and along small blood vessel of organs. They contain chemicals such as *heparin, histamine* and *proteolytic enzymes*. These substances are released in response to injury, such as trauma and infection, and play important role in inflammation.

- ✓ **White blood cells** or leukocytes continuously move from blood vessels into connective tissues. The rate of movement increases dramatically in response to injury or infection.
- ✓ **Macrophage**s are found in some connective tissue types. They are derived from monocytes, a white blood cell type. They can be fixed and do not move through the connective tissue in which they are found or are wandering macrophages and moves by ameboid movement through the connective tissue. Macrophages phagocytize foreign and injured cells, and they play a major role in providing protection against infection.

- ✓ **Undifferentiated mesenchymal cel**l, sometimes called ***stem cells*** are embryonic cells that persist in adult connective tissue. They have the potential to differentiate to form adult cell types, such as fibroblasts or smooth muscle cells, in response to injury.

Extracellular matrix

The extracellular matrix of connective tissue has three major components:

1. Protein fibers
2. Ground substance consisting of nonfibrous protein and other molecule and
3. Fluid.

The structure of the matrix gives connective tissue types most of their functional characteristics, such as the ability of bones and cartilage to bear weight, of tendons and ligaments to withstand tension, and of the skin's dermis to withstand punctures, abrasions, and other abuse.

1.2.2.2 Classification of connective tissues

Classification schemes for connective tissue are influenced by:

1. Protein fibers and the arrangement of protein fibers in the extracellular matrix;
2. Protein fibers and ground substance in the extracellular matrix;
3. A fluid extracellular matrix.

The two major categories of connective tissue are ***embryonic*** and ***adult connective tissue***.

- ✓ **Embryonic connective tissue** is called mesenchyme. It is made up of irregularly shaped fibroblastes surrounded by abundant semifluid extracellular matrix in which delicate collagen fibers are distributed. It forms in the embryo during the 3rd and 4th weeks of development from mesoderm and neural crest cells and all adult connective tissue types develop from it. By 8 weeks of development, most of the mesenchyme has become specialized to form the types of connective tissue seen in adults, as well as muscle, blood vessels, and other tissues.

- ✓ **Adult connective tissue** consists of six types: loose, dense, connective tissue with special properties, cartilage, bone and blood and hemopoietic tissue.

Classification of connective tissues

Major categories of connective tissues	**Categories of connective tissues**	**Subcategories**	**Structure**	**Function**	**Location**
Embryonic connective tissue	Mesenchyme		The mesenchymal cells are irregularly shaped; the extracellular matrix is abundant and contains scattered reticular fibers.	Origin of all types of adult connective tissues.	Mesenchyme is the embryonic tissue from which connective tissues, as well as other tissues arise.
	Mucous		Mucous tissue is mesenchymal tissue that remains unspecialized; the cells are irregularly shaped; the extracellular matrix is abundant and contains scattered reticular fibers.		Umbilical cord of newborn.
Adult connective tissue	Loose connective tissue		Cells (e.g. fibroblasts, macrophages, and lymphocytes) within a fine network of mostly collagen fibers; often merges with denser connective tissue.	Loose packing, support and nourishment for the structures with which it is associated. packing, support, and nourishment	Widely distributed throughout the body; substance on which epithelial basement membranes rest; packing between glands, muscles, and nerves; attaches the skin to underlying tissues

	Dense connective tissue	Dense , regular collagenous	Matrix composed of collagen fibers running in somewhat the same direction.	Ability to withstand great pulling forces exerted in the direction of fiber orientation, great tensile strength and stretch resistance.	Tendons (attach muscle to bone) and ligaments (attach bones to each other).
		Dense, regular elastic	Matrix composed of regularly arranged collagen fibers and elastin fibers.	Capable of stretching and recoiling like a rubber band, with the strength in the direction of the fiber orientation.	Ligaments between the vertebrae and along the dorsal aspect of the neck (nucha) and in the vocal cords.
		Dense , irregular collagenous	Matrix composed of collagen fibers that run in all directions or in alternating planes of fibers oriented in somewhat single direction.	Tensile strength capable of withstanding stretching in all directions.	Sheaths; most of the dermis of the skin; organ capsules and septa; outer covering of body tubes.
		Dense , irregular elastic	Matrix composed of bundles and sheets of collagenous and elastin fibers oriented in multiple directions.	Capable of strength with stretching and recoil in several directions.	Elastic arteries.

	Special properties	Adipose	Little extracellular matrix surrounding cells; the adipocytes, or fat cells, are so full of lipid that the cytoplasm is pushed to the periphery of the cell.	Packing material, thermal insulator, Energy storage and protection of organs against injury from being bumped or jarred.	Predominantly, in subcutaneous areas; in mesenteries, in renal pelvis, around kidney; attached to the surface of the colon, in mammary glands, in loose connective tissue that penetrates into spaces and crevices.
		Reticular	Fine network of reticular fibers irregularly arranged.	Provide a superstructure for the lymphatic and hemopoietic.	Within the lymph, node, spleen and bone marrow.
	Cartilage	Hyaline	Collagen fibers are small and evenly dispersed in the matrix, making the matrix appear transparent; the cartilage cells, or chondrocytes, are found in spaces, or lacunae, within the firm but flexible matrix.	Allows growth of long bones; provide rigidity with some flexibility in the trachea, bronchi, ribs, and nose; forms rugged, smooth, yet somewhat flexible articulating surfaces; forms the embryonic skeleton.	Growing long bones, cartilages rings of the respiratory system, costal cartilage of ribs, nasal cartilages, articulating surface of bones, embryonic skeleton.
		Fibrocartilage	Collagenous fibers similar to those in hyaline cartilage, the fibers are more numerous than in other cartilages and are	Somewhat flexible and capable of withstanding, considerable pressure, connects structures subjected	Intervertebral disk, symphysis pubis, articular disk, (e.g. knee and temporomendibular(jaw)

			arranged in thick bundles.	to great pressure.	joints)
		Elastic	Similar to hyaline cartilage, but matrix also contains elastin fibers.	Provide rigidity even more flexibility than hyaline cartilage because elastic fibers return to their original shape after being stretched.	External ears, epiglottis, auditory tubes.
	Bone	Cancellous	Lattice like network of scaffolding characterized by trabeculae with large spaces between them filled by hemopoietic tissues; the osteocytes, or bone cells, are located within lacunae in the trabeculae.	Acts as a scaffolding to provide strength and support without the greater weight of compact bone.	In the interior of the bones of the skull, vertebrae, sternum, and pelvis, and in the ends of the long bones.
		Compact	Hard, bony matrix predominates; many osteocytes are located within lacunae that are distributed in a circular fashion around the central canals; small passageways connect adjacent lacunae.	Provides great strength and support; forms a solid outer shell on bones that keeps them from being easily broken or puncture.	Outer portions of all bones, the shafts of long bones.
	Blood		Blood cells and a fluid matrix.	Transports oxygen, carbon dioxide, hormones, nutrients,	Within the blood vessels; produced by the

				waste products, and other substances; protects the body from infections and is involved in temperature regulation.	hemopoietic tissues; white blood cells frequently leave the blood vessels and enter the interstitial spaces.
	Bone Marrow		Reticular framework with numerous blood-forming cells (red marrow)	Production of new blood cells (red marrow); lipid storage(yellow marrow)	Within marrow cavities of bone, two types: red marrow (hemopoietic or blood-forming tissue) in the end of long bones and in short, flat and irregularly shaped bones, yellow marrow is mostly adipose tissue and is found in the shafts of long bones.

1.2.2.3 Types of connective tissue

Type	Structure	Location and Function
Blood	Plasma (matrix) and red blood cells, RBCs, and platelets	Within blood vessels • *Plasma*—transports materials • *RBCs*—carry oxygen • *WBCs*—destroy pathogens • *Platelets*—prevent blood loss
Areolar (loose)	Fibroblasts and a matrix of tissue fluid, collagen, and elastin fibers	Subcutaneous • Connects skin to muscles; WBCs destroy pathogens. Mucous membranes (digestive, respiratory, urinary, reproductive tracts) • WBCs destroy pathogens
Adipose	Adipocytes that store fat (little matrix)	Subcutaneous • Stores excess energy • Produces chemicals that influence appetite, use of nutrients, and inflammation. Around eyes and Kidneys • Cushions
Fibrous	Mostly collagen fibers (matrix) with few fibroblasts	Tendons and ligaments (regular) • Strong to withstand forces of movement of joints. Dermis (irregular) • The strong inner layer of the skin
Elastic	Mostly elastin fibers (matrix) with few fibroblasts	Walls of large arteries • Helps maintain blood pressure Around alveoli in lungs • Promotes normal exhalation
Bone	Osteocytes in a matrix of calcium salts and collagen	Bones • Support the body • Protect internal organs from mechanical injury • Store excess calcium • Contain and protect red bone marrow
Cartilage	Chondrocytes in a flexible protein matrix	Wall of trachea • Keeps airway open. On joint surfaces of bones • Smooth to prevent friction. Tip of nose and outer ear • Support Between vertebrae • Absorb shock

1.2.3 Muscle tissue

Muscle tissue is composed of cells that have the special ability to shorten or contract in order to produce movement of the body parts. The tissue is highly cellular and is well supplied with blood vessels. The cells are long and slender so they are sometimes called muscle fibers, and these are usually arranged in bundles or layers that are surrounded by connective tissue. *Actin* and *myosin* are contractile proteins in muscle tissue.

Muscle tissue can be categorized into skeletal muscle tissue, smooth muscle tissue, and cardiac muscle tissue.

Skeletal muscle fibers are cylindrical, multinucleated, striated, and under voluntary control. **Smooth muscle** cells are spindle shaped, have a single, centrally located nucleus, and lack striations. They are called involuntary muscles. **Cardiac muscle** has branching fibers, one nucleus per cell, striations, and intercalated disks. Its contraction is not under voluntary control.

Comparison of Muscle types

Criteria	**Skeletal Muscle**	**Cardiac Muscle**	**Smooth Muscle**
Location	Attached to bones	Heart	Walls of hollow organs, blood vessels, eyes, glands, skin.
Cell shape	Very long, cylindrical cells I1-4 cm and may extend the entire length of the muscle; 10-100um in diameter)	Cylindral cells that branch (100-500 um in length; 12-20um in diameter)	Spindle-shaped cells (15-200um in length; 5-8umin diameter)
Nucleus	Multinucleated, peripherally located	Single, centrally located	Single, centrally located
Striations	Yes	Yes	No
Control	Voluntary (conscious)	Involuntary (unconscious)	Involuntary (unconscious)
Ability to contract spontaneously	No	Yes	Yes
Function	Body movement	Contraction provides the major force for moving blood trough the blood	Movement of food through the digestive tract, emptying of the urinary bladder

		vessels.	regulation of blood vessel diameter, change in pupil size, contraction of many gland ducts, movement of hair, and many more functions.
Special Features		Branching fibers, intercalated disks containing gap junctions joining the cells to each other.	Gap junctions.

1.2.4 Nervous tissue

The nervous tissue is found in the brain, spinal cord and nerves. It is characterized by the ability to conduct electric signals called **action potentials**. It consists of *neurons*, which are responsible for this conductive ability, and support cells called *neuroglia*.

Neurons or nerve cells are the conducting cells of nervous tissue. They are composed by three major parts: cell body, dendrites and axon. The cell body contains the nucleus and is the site of general cell functions. Dendrites and axons are two types of nerve cell processes, both consisting of projections of cytoplasm surrounded by membrane. **Dendrites** usually receive the action potentials. **Axons** usually conduct action potentials away from the cell body.

Neurons that posses several dendrites and one axon are called ***multipolar neurons***. Neurons that posses a single dendrite and an axon are called ***bipolar neurons***. Some very specialized neurons, called ***unipolar neurons*** have only one axon and no dendrites.

Neuroglia are the support cells of the brain, spinal cord, and peripheral nerves. Neuroglia nourish, protect, and insulates neurons.

Nervous tissue

Part	**Structure**	**Function**
Cell body of the neuron	Contains the nucleus	• Regulates the functioning of the neuron
Axon of the neuron	Cellular process (extension)	• Carries impulses away from the cell body
Dendrites of the neuron	Cellular process (extension)	• Carry impulses toward the cell body

Synapse	Space between axon of one neuron and the dendrite or cell body of the next neuron	• Transmits impulses from one neuron to others
Neurotransmitters	Chemicals released by axons	• Transmit impulses across synapses
Neuroglia	Specialized cells in the central nervous System	• Form myelin sheaths and other functions
Schwann cells	Specialized cells in the peripheral nervous system	• Form the myelin sheaths around neurons

2. MEMBRANES

A membrane is a thin sheet or layer of tissue that covers a structure or lines a cavity. Most membranes are formed from epithelium and the connective tissue on which it rests. The skin or cutaneous membrane is the external membrane. The three categories of internal membranes are *mucous membranes*, *serous membranes*, and *synovial membranes.*

2.1 Epithelial Membranes

Epithelial membranes consist of epithelial tissue and the connective tissue to which it is attached. The two main types of epithelial membranes are the mucous membranes and serous membranes.

Mucous Membranes

Mucous membranes are epithelial membranes that consist of epithelial tissue that is attached to an underlying loose connective tissue. These membranes, sometimes called mucosae, line the body cavities that open to the outside. The entire digestive tract is lined with mucous membranes. Other examples include the respiratory, excretory, and reproductive tracts.

Serous Membranes

Serous membranes line body cavities that do not open directly to the outside, and they cover the organs located in those cavities. Serous membranes are covered by a thin layer of serous fluid that is secreted by the epithelium. Serous fluid lubricates the membrane and reduces friction and abrasion when organs in the thoracic or abdominopelvic cavity move against each other or the cavity wall. Serous membranes have special names given according to their location. For example, the serous membrane that lines the thoracic cavity and covers the lungs is called pleura.

2.2 Connective Tissue Membranes

Connective tissue membranes contain only connective tissue. Synovial membranes and meninges belong to this category.

A. **Synovial Membranes**.

Synovial membranes are connective tissue membranes that line the cavities of the freely movable joints such as the shoulder, elbow, and knee. Like serous membranes, they line cavities that do not open to the outside. Unlike serous membranes, they do not have a layer of epithelium. Synovial membranes secrete synovial fluid into the joint cavity, and this lubricates the cartilage on the ends of the bones so that they can move freely and without friction.

B. **Meninges**.

The connective tissue covering on the brain and spinal cord, within the dorsal cavity, are called ***meninges***. They provide protection for these vital structures.

Connective tissue membranes

Membrane	**Location and Function**
Superficial fascia	• Between the skin and muscles; adipose tissue stores fat
Periosteum	• Covers each bone; contains blood vessels that enter the bone • Anchors tendons and ligaments
Perichondrium	• Covers cartilage; contains capillaries, the only blood supply for cartilage
Synovial	• Lines joint cavities; secretes synovial fluid to prevent friction when joints move

Deep fascia	• Covers each skeletal muscle; anchors tendons
Meninges	• Cover the brain and spinal cord; contain cerebrospinal fluid
Fibrous pericardium	• Forms a sac around the heart; lined by the serous parietal pericardium